

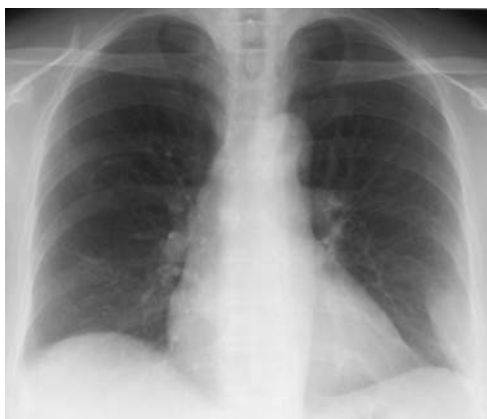# A 59-year-old female with cough and left-sided chest pain

## Case history

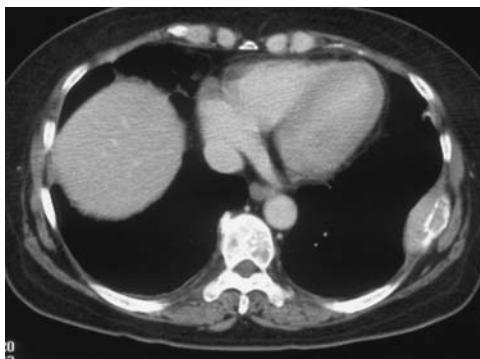A 59-year-old female was admitted with symptoms of cough and left-sided chest pain of 2 weeks' duration in March 2006. The remainder of her history was not contributory. Physical examination was normal, except for left lateral chest tenderness.

## Investigation

The patient's chest radiograph is shown in figure 1, and the chest computed tomography (CT) scan is shown in figure 2.



**Figure 1**  
Chest radiograph.



**Figure 2**  
Chest CT scan.

### Task 1

Interpret the chest radiograph and CT scan.

### Task 2

Suggest differential diagnoses.

K. Maki<sup>1</sup>  
T. Harada<sup>1</sup>  
Y. Akiyama<sup>1</sup>  
H. Ogasawara<sup>1</sup>  
F. Kishi<sup>1</sup>  
M. Ohe<sup>2</sup>

Sections of <sup>1</sup>Respiratory Diseases and <sup>2</sup>Hematology, Dept of Internal Medicine, Hokkaido Social Insurance Hospital, Sapporo, Japan.

### Correspondence

T. Harada  
Section of Respiratory Diseases  
Dept of Internal Medicine  
Hokkaido Social Insurance  
Hospital  
3-18, 1-8, Nakanoshima  
Toyohira-ku  
Sapporo 062-8618  
Japan  
Fax: 81 118213851  
E-mail:  
t-harada@hok-shaho-hsp.jp

### Competing interests

None declared

### Provenance

Submitted article, peer reviewed

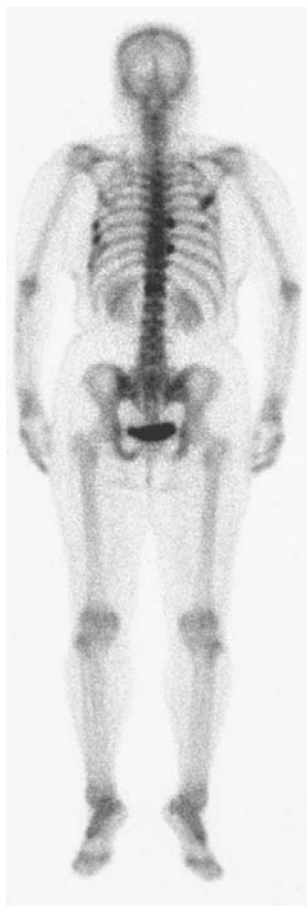### Answer 1

The chest radiograph reveals extrapleural mass at the left lower field. Chest CT scan reveals an osteolytic change in the left ninth rib associated with a localised soft tissue mass.

### Answer 2

The differential diagnosis includes metastatic bone tumour, osteoncus (neoplasm of bone origin) and neoplasms of pleural, chest wall or medullary origin.

The results of clinical investigations included: positive urinary protein; erythrocyte sedimentation rate 56 mm per h; immunoglobulin-G 2,720 mg per dL (normal: 870–1,700 mg per dL); and zinc sulphate turbidity test 21.6 U per mL (normal: 0.0–12.0 U per mL). Complete blood cell count and several tumour markers were normal. On technetium-99m bone scintigraphy, several ribs, including the left ninth rib and the vertebrae, showed uptake. The posterior view is shown in figure 3. Abdominal CT and brain magnetic resonance imaging were normal.



**Figure 3**  
Technetium-99m bone scintigraphy, posterior view.

### Task 3

Based on the results of the investigations, suggest a diagnosis.

### Task 4

Propose additional examinations.

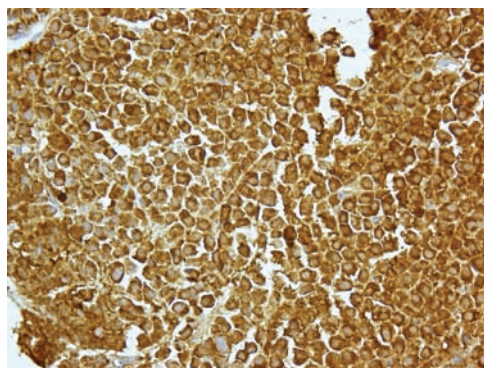
### Answer 3

The diagnosis is multiple myeloma.

### Answer 4

Serum and urinary immunoelectrophoresis, bone marrow aspiration, and a biopsy of the soft tissue mass surrounding the left ninth rib should be carried out.

Serum and urinary immunoelectrophoresis showed a monoclonal protein pattern (immunoglobulin G type, Bence-Jones type). On the bone marrow aspiration cell differential, there was a marked increase in plasma cells with an atypical appearance (27.5%). The biopsy specimens obtained from the soft tissue mass revealed monoclonal plasma cells that had positive-chain staining (figure 4). These findings are consistent with multiple myeloma.



**Figure 4**  
Biopsy specimens obtained from the soft tissue mass.

### Clinical course

The patient was treated with three courses of the VAD regimen every 3 weeks: vincristine 0.3 mg per m<sup>2</sup>, days 1–4; adriamycin 9 mg per m<sup>2</sup>, days 1–4; and dexamethasone 20 mg per day, days 1–4). Her symptoms rapidly improved and the number of atypical plasma cells present in the bone marrow dramatically diminished. Subsequently, she was treated with cyclophosphamide (1,000 mg per m<sup>2</sup>) following a peripheral blood stem cell harvest. The planned treatment was high-dose chemotherapy supported by autologous stem cell transplantation. As of December 2007, the patient remained in good condition and had no disease recurrence.

## Discussion

Thoracic involvement in multiple myeloma is not rare. In one review of 958 patients with multiple myeloma, evidence of skeletal or pleuropulmonary abnormality was found during the course of the disease in 443 (46%), and radiographic abnormalities were present in 25% at the time of initial diagnosis. Thoracic skeletal involvement was seen on chest radiography in 267 (28%) patients; the most frequent abnormality was an osteolytic lesion, which was seen in 146 (55%). In multiple myeloma patients, the ribs, either singly or in combination, are the thoracic structures that have been reported to be most commonly involved [1]. Rib involvement can cause local tenderness and pain on respiration, as in the present case.

In older patients, the association of a destructive lesion of one or more ribs with a soft tissue mass that protrudes into the thorax and indents the lung is highly suggestive of myeloma [2]. However, a primary pulmonary carcinoma that invades the chest wall can have a similar appearance, as can other primary or metastatic chest wall neoplasms. In one series of 47 patients, who had a peripheral pulmonary carcinoma that came in contact with

the pleural surface or chest wall, the following were associated with a sensitivity of 87% and a specificity of 59% for chest wall invasion: the presence of an obtuse angle between the mass and the pleura; tumour contact with the pleura over a distance >3 cm; and pleural thickening [3].

In patients with multiple myeloma, as the myelomatous tumour of the chest wall extends inwardly, it forms a subpleural mass that displaces the pleural layers from their usual location adjacent to the chest wall. On radiography, the soft tissue component is often the most readily detectable portion of the lesion [2]. The soft tissue tumour of a myelomatous chest wall lesion is larger or more conspicuous than a chest wall metastatic tumour. Though each lesion will show rib destruction, there is little or no soft tissue mass associated with a metastatic lesion [4]. WOLFEL and DENNIS [2] emphasised this point and have suggested that it is a practical means of differentiating between myeloma and metastatic malignancy of the chest wall. Multiple myeloma should be kept in mind when considering the differential diagnosis of osteolytic processes of the rib that are associated with a soft tissue mass.

## References

1. Kintzer JS Jr, Rosenow EC 3rd, Kyle RA. Thoracic and pulmonary abnormalities in multiple myeloma. A review of 958 cases. *Arch Intern Med* 1978; 138: 727-730.
2. Wolfel DA, Dennis JM. Multiple myeloma of the chest wall. *Am J Roentgenol* 1963; 89: 1241-1245.
3. Glazer HS, Duncan-Meyer J, Aronberg DJ, Moran JF, Levitt RG, Sagel SS. Pleural and chest wall invasion in bronchogenic carcinoma: CT evaluation. *Radiology* 1985; 157: 191-194.
4. Williams ER. Multiple myeloma; Robert Knox Memorial Lecture. *T Fac Radiologists* 1958; 9: 2-12.