

Editorial

Protracted bacterial bronchitis is a precursor for bronchiectasis in children: myth or maxim?

Introduction

“... from present knowledge, it seems justifiable to state that with better social conditions and prophylactic care much irreversible bronchiectasis can be prevented while with judicious treatment and skilled surgery many can be cured. Even with simple treatment the progress of most cases can be arrested, some showing considerable improvement and a few being clinically cured ...”

Elaine Field in 1949 [1]

Although protracted bacterial bronchitis (PBB) was only first recognised as a clinical diagnostic entity in 2006 [2], astute clinicians described PBB-like conditions decades ago and postulated they were part of a pre-bronchiectatic state [1, 3]. The link between PBB and bronchiectasis was formally proposed a decade ago [4], and this paradigm is now increasingly accepted [5, 6]. Is this link (or spectrum) a myth or maxim?

Data from days gone by

While publications from days gone by did not refer to PBB as such, the condition clearly existed. Historically, astute clinicians described PBB-like conditions but did not define it as a clinical entity. Field's 1940s series on paediatric bronchiectasis described the concept of a

pre-bronchiectasis state [1, 3] and advocated aggressive treatment (predominantly antibiotics) for prevention and cure of bronchiectasis. In the same era, FINK [7] opened his paper with the statement “The common background of chronic bronchitis and bronchiectasis is, in the majority of cases, non-tuberculous bronchopulmonary infection”. In that era, tools that are now widely available (*e.g.* flexible bronchoscopy and bronchoalveolar lavage (BAL) assessments) were non-existent. Almost 40 years ago, TAUSSIG *et al.* [8] highlighted the various definitions of “childhood chronic bronchitis” doctors used, ranging from “productive cough for 3-months in a year” to “recurrent episodes of cough lasting for >2-weeks” and wheezing.

Further to the clinical associations described above, the BAL characteristics of PBB were also described with the advent of bronchoscopy prior to PBB being defined. BOOGAARD *et al.* [9] described chronic bacterial bronchitis in children with tracheobronchomalacia. FAYON *et al.* [10] found that ~13% of children undergoing bronchoscopy for “severe chronic asthma” had lower airway infection (defined as $>10^4$ cfu·mL⁻¹ BAL with activated neutrophils). These features (infection and airway neutrophilia) are also PBB BAL features [11]. In the context that PBB is still often misdiagnosed as asthma [12], and that parents of children with PBB have often described wheezing illness [11, 13], some of the children in the study by FAYON *et al.* [10] probably had PBB and/or bronchiectasis.

Cite as: Chang AB, Marchant JM. Protracted bacterial bronchitis is a precursor for bronchiectasis in children: myth or maxim? *Breathe* 2019; 15: 167–170.

 @ERSpublications

Recognising the link between protracted bacterial bronchitis and bronchiectasis creates an opportunity to understand the pathobiology of early suppurative endobronchial lung disease and prospects for the development of effective and early interventions <http://bit.ly/2K3ikI6>



CrossMark



© ERS 2019

What is PBB and is it real?

The original three criteria for PBB arose from clinical observations and now each criterion has been validated [11]. These criteria are: 1) the presence of chronic wet/productive cough; 2) bacterial infection in the BAL; and 3) cough resolved following 2 weeks of antibiotics [2]. Although not without initial controversy, PBB is now incorporated into many paediatric chronic cough guidelines [11, 14]. PBB is also accepted by the American College of Chest Physicians [14] and the European Respiratory Society (ERS) as a clinical entity through its incorporation into the ERS paediatric curriculum in 2012 and a task force document [15].

Subsequent to our original description [2], others (in the USA, China and Europe) [11] also described PBB. Currently, PBB is subclassified (PBB-clinical, PBB-micro, PBB-extended) [11] as it is not feasible to obtain lower airway cultures from every child with a chronic wet cough (>4 weeks duration), and the recognition that 4 weeks of antibiotics is required to resolve their cough in a minority of patients [14].

Biological plausibility

The pathognomonic chest computed tomography feature of bronchiectasis is abnormal dilatation of the airways, expressed as an increased bronchoarterial ratio (BAR) of >0.8 in children [5]. BAR increases with increasing severity of bronchiectasis [5]. That is, from a normal mean BAR of 0.5–0.6 in children [16], the gradual increase (other than for congenital forms of bronchiectasis, *e.g.* Mounier-Kuhn syndrome) occurs when the airway insults (usually infection and inflammation) are uncurtailed. Recurrent and/or persistent infection are part of the “vicious cycle” of airway

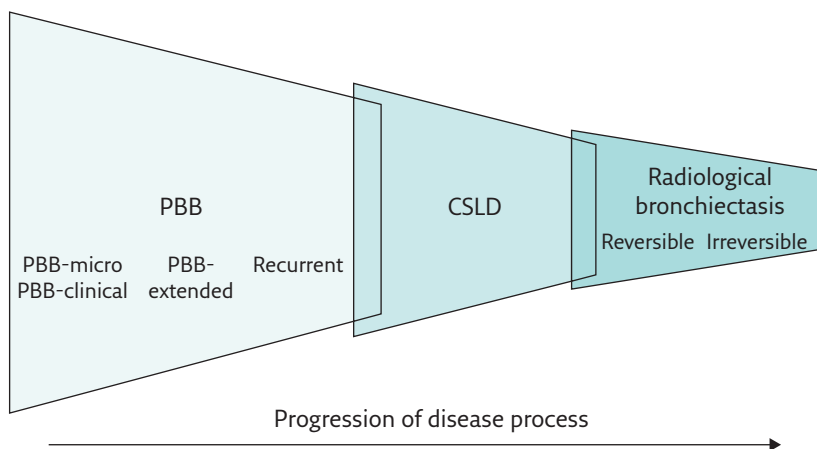


Figure 1 Using the pathobiological model, PBB, chronic suppurative lung disease (CSLD) and radiographically confirmed bronchiectasis probably represent different ends of a spectrum with similar underlying mechanisms of airway neutrophilia, endobronchial bacterial infection and impaired mucociliary clearance. Untreated it is likely some (but not all) children with PBB will progress to develop CSLD and some will ultimately develop bronchiectasis, initially reversible and subsequently irreversible if left to progress. There is a degree of overlap between each of the entities. Reproduced from [11] with permission from the publisher.

injury associated with bronchiectasis [5]. At some point during this process, lung injury is so advanced that the tissue changes become irreparable (irreversible bronchiectasis).

That PBB represents the early spectrum of chronic endobronchial suppurative disease, and irreversible bronchiectasis the opposite late end, is logical and biologically plausible (figure 1). Mild radiological bronchiectasis in children is reversible if treated early, thereby avoiding the later progressive decline in lung function [6]. Adults with bronchiectasis symptoms from childhood have worse disease and poorer prognosis (compared with adult-onset patients) [17]. Once bronchiectasis is severe (*e.g.* adults with established bronchiectasis), the pathobiology (*e.g.* airway microbiota [18]) is different. The following sections further illustrate this maxim with PBB and early bronchiectasis having shared clinical, bacterial, inflammatory and pathobiological features, that later diverge with increasing bronchiectasis severity.

Data linking PBB to bronchiectasis

Clinical

PBB and mild/early cylindrical bronchiectasis share clinical features and are indeed indistinguishable at first visit when bronchiectasis is not related to an underlying illness (*e.g.* immunodeficiency, primary ciliary dyskinesia). These common features are chronic wet/productive cough, reports of wheeze/rattles and the child appears otherwise well without digital clubbing [11, 13]. Chest radiographs generally show only perihilar changes [19], and spirometry is normal [11, 19, 20], as are respiratory system reactance and resistance measured by the forced oscillatory technique (unpublished data from the authors' research group). Also, both groups have impaired cough-specific and generic quality of life scores, which improve significantly with cough resolution [11, 20].

The chronic cough in most children with PBB resolves when treated with 2 weeks of an appropriate antibiotic (usually amoxicillin-clavulanic acid) targeting the common respiratory pathogens [11]. Some require a 4-week course [14]. When the child's chronic wet/productive cough does not resolve following 4 weeks of antibiotics, the adjusted odds ratio of having bronchiectasis (compared with children whose wet cough resolves) is 20.9 (95% CI 5.4–81.8). Recurrent PBB is a risk factor for future bronchiectasis (adjusted OR 11.5, 95% CI 2.3–56.5) [21]. Between PBB and bronchiectasis, lies the entity of chronic suppurative endobronchial lung disease (defined as the presence of symptoms and signs of bronchiectasis with the absence of radiographic evidence of bronchiectasis) [22], where intravenous antibiotics are required to resolve the child's chronic wet/productive cough. With advanced bronchiectasis

severity, additional features (*e.g.* digital clubbing, abnormal spirometry) may then appear [6].

Microbiology

In addition to clinical features, the lower airway microbiology of PBB and mild bronchiectasis are also similar [6, 11]. In both, *Streptococcus pneumoniae*, *Haemophilus influenzae* (mostly non-typable, NTHi) and *Moraxella catarrhalis* were the main bacteria detected in BAL specimens [6, 11]. Further, the lower airway core and satellite microbiota of children with PBB and bronchiectasis are similar based on bacterial 16S rRNA gene pyrosequencing and phylogenetic analysis [18]. This contrasts with adult data (with more severe disease) where the pulmonary microbiome is divergent from children with the same disease [18]. Also, with increasing severity of bronchiectasis, *Pseudomonas aeruginosa* infection becomes more common. Further, prospective studies found adenovirus was commonly co-detected with *S. pneumoniae*, *H. influenzae* or *M. catarrhalis* in BAL samples from young children with PBB or bronchiectasis [23]. Upon genotyping, adenovirus in both conditions belonged predominantly to species C [23].

Pathobiology

Tracheobronchomalacia commonly coexists with PBB and bronchiectasis [11, 13, 24], but as data is limited to cross-sectional cohort studies, cause and effect is unknown.

The lower airway profile of PBB and bronchiectasis [5] is characterised by intense neutrophilic inflammation with marked pro-inflammatory mediator responses (*e.g.* interleukin (IL)-8, matrix metalloproteinase-9 and IL-1 β) [25, 26]. Experimental and validation cohorts of children with PBB have significantly higher levels of gene and protein expression of IL-1 β , α -defensin, IL-1 pathway members and CXCR2 than non-PBB disease controls [26]. The gene expression of the IL-1 β signalling molecules pellino-1 and IL-1 receptor associated kinase 2 were significantly higher in those with recurrent (>3 episodes per year) PBB (*versus* those without) [26], of whom 85% eventually had bronchiectasis within 2 years [21]. Like clinical and microbial data, this also suggests a dose-response phenomena with PBB at one end and bronchiectasis at the other.

Further, concurrent experiments found that the pathobiological responses of lower airway specimens

from children with PBB and bronchiectasis share similarities and significantly differ to controls. Impaired apoptosis and efferocytosis to NTHi [27] and gene expression levels of NTHi-stimulated BAL airway cells [28] from children with PBB were in between the values of controls and those with bronchiectasis.

The limitations: it looks the same but is it the same?

Although PBB shares many similarities with early bronchiectasis, cause and effect is unproven. Also, given the availability of computed tomography scans, there is currently only one prospective study, no animal models and human experimental evidence would be unethical to most. There is little doubt that the host response plays a critical role [6], but data from ~70 years ago [1, 7], supported by more recent data [6], dispels the opinion that bronchiectasis eventually develops in those predestined to do so and that PBB is unrelated. Nevertheless, there is little doubt that more in-depth studies and long-term cohort studies are needed. Clinically, some children with PBB also eventually have an asthma phenotype (recognised decades ago as wheezy bronchitis) and whether they then develop a chronic obstructive pulmonary disease (COPD)-like phenomenon remains speculative. Indeed, adults with COPD also share some similarities (*e.g.* NTHi infection, dysfunctional efferocytosis, and neutrophilic inflammation).

Summary

PBB is linked with, and highly likely a forerunner of, bronchiectasis. Untreated chronic wet cough (PBB) with ongoing bacterial infection and associated neutrophilic inflammation would lead to eventual airway damage (bronchiectasis). However, absolute proof is lacking and indeed is highly likely never to be proven. Nevertheless, the biological plausibility is convincing, supported by clinical, lower airway microbiology and pathobiological aspects. Recognising the link between PBB and bronchiectasis creates an opportunity for understanding the pathobiology of early suppurative endobronchial lung disease and consequently increases the prospects of developing effective and early interventions. Unless future data disproves the paradigm linking PBB with bronchiectasis [6], this link is a maxim.

Affiliations

Anne B. Chang^{1,2,3}, Julie M. Marchant^{1,2}

¹Dept of Respiratory and Sleep Medicine, Queensland Children's Hospital, Brisbane, Australia. ²Center for Children's Health Research, Queensland University of Technology, Brisbane, Australia. ³Child Health Division, Menzies School of Health Research, Darwin, Australia.

Conflict of interest

A.B. Chang reports grants from National Health and Medical Research Council, Australia related to the submitted work (multiple grants relating to cough, bronchiectasis and PBB). Other grants and interests from GSK (member of a data monitoring committee relating to an unlicensed vaccine), Up to Date (author of sections on paediatric cough) and BMJ Evidence Centre (author of two chapters on paediatric asthma with monies received by her institution) are outside the submitted work. J.M. Marchant reports other from Up to Date (author of sections on paediatric cough), outside the submitted work.

Support statement:

J.M. Marchant is supported by a Children's Hospital Foundation Queensland fellowship (RPC0772019). A.B. Chang is supported by a NHMRC practitioner fellowship (APP1154302) and a Children's Hospital Foundation Queensland top-up fellowship grant (50286). None of the authors received an honorarium or other form of payment to produce the manuscript.

References

- Field CE. Bronchiectasis in childhood; prophylaxis, treatment and progress with a follow-up study of 202 cases of established bronchiectasis. *Pediatrics* 1949; 4: 355-372.
- Marchant JM, Masters IB, Taylor SM, *et al.* Evaluation and outcome of young children with chronic cough. *Chest* 2006; 129: 1132-1141.
- Field CE. Bronchiectasis in childhood; aetiology and pathogenesis, including a survey of 272 cases of doubtful irreversible bronchiectasis. *Pediatrics* 1949; 4: 231-248.
- Chang AB, Redding GJ, Everard ML. State of the Art - Chronic wet cough: protracted bronchitis, chronic suppurative lung disease and bronchiectasis. *Pediatr Pulmonol* 2008; 43: 519-531.
- Chalmers JD, Chang AB, Chotirmall SH, *et al.* Bronchiectasis. *Nature Rev Dis Primers* 2018; 4: 45.
- Chang AB, Bush A, Grimwood K. Bronchiectasis in children: diagnosis and treatment. *Lancet* 2018; 392: 866-879.
- Finke W. Prospects for prevention of chronic bronchitis and bronchiectasis; rational management of bronchopulmonary infections by penicillin aerosol therapy. *J Pediatr* 1948; 33: 29-42.
- Taussig LM, Smith SM, Blumenfeld R. Chronic bronchitis in childhood: what is it? *Pediatrics* 1981; 67: 1-5.
- Boogaard R, Huijsmans SH, Pijnenburg MW, *et al.* Tracheomalacia and bronchomalacia in children: incidence and patient characteristics. *Chest* 2005; 128: 3391-3397.
- Fayon M, Just J, Thien HV, *et al.* Bacterial flora of the lower respiratory tract in children with bronchial asthma. *Acta Paediatr* 1999; 88: 1216-1222.
- Chang AB, Upham JW, Masters IB, *et al.* Protracted bacterial bronchitis: the last decade and the road ahead. *Pediatr Pulmonol* 2016; 51: 225-242.
- Donnelly DE, Critchlow A, Everard ML. Outcomes in children treated for persistent bacterial bronchitis. *Thorax* 2007; 62: 80-84.
- Wurzel D, Marchant JM, Yerkovich ST, *et al.* Prospective characterisation of protracted bacterial bronchitis in children. *Chest* 2014; 145: 1271-1278.
- Chang AB, Oppenheimer JJ, Weinberger MM, *et al.* Management of children with chronic wet cough and protracted bacterial bronchitis: CHEST Guideline and Expert Panel Report. *Chest* 2017; 151: 884-890.
- Kantar A, Chang AB, Shields MD, *et al.* ERS statement on protracted bacterial bronchitis in children. *Eur Respir J* 2017; 50: 1602139.
- Kapur N, Masel JP, Watson D, *et al.* Bronchoarterial ratio on high resolution CT scan of the chest in children without pulmonary pathology - need to redefine bronchial dilatation. *Chest* 2011; 139: 1445-1450.
- King PT, Holdsworth SR, Farmer M, *et al.* Phenotypes of adult bronchiectasis: onset of productive cough in childhood and adulthood. *COPD* 2009; 6: 130-136.
- van der Gast CJ, Cuthbertson L, Rogers GB, *et al.* Three clinically distinct chronic pediatric airway infections share a common core microbiota. *Ann Am Thorac Soc* 2014; 11: 1039-1048.
- Chang AB, Robertson CF, van Asperen PP, *et al.* Children with chronic cough: when is watchful waiting appropriate? Development of likelihood ratios for assessing children with chronic cough. *Chest* 2015; 147: 745-753.
- Goyal V, Grimwood K, Masters IB, *et al.* State of the art: pediatric bronchiectasis. *Pediatr Pulmonol* 2016; 51: 450-469.
- Wurzel DF, Marchant JM, Yerkovich ST, *et al.* Protracted bacterial bronchitis in children: Natural history and risk factors for bronchiectasis. *Chest* 2016; 150: 1101-1108.
- Goyal V, Grimwood K, Marchant JM, *et al.* Paediatric chronic suppurative lung disease: clinical characteristics and outcomes. *Eur J Pediatr* 2016; 175: 1077-1084.
- Wurzel DF, Mackay IM, Marchant JM, *et al.* Adenovirus species C is associated with chronic suppurative lung diseases in children. *Clin Infect Dis* 2014; 59: 34-40.
- Kompare M, Weinberger M. Protracted bacterial bronchitis in young children: association with airway malacia. *J Pediatr* 2012; 160: 88-92.
- Marchant JM, Gibson PG, Grissell TV, *et al.* Prospective assessment of protracted bacterial bronchitis: airway inflammation and innate immune activation. *Pediatr Pulmonol* 2008; 43: 1092-1099.
- Baines KJ, Upham JW, Yerkovich ST, *et al.* Mediators of neutrophil function in children with protracted bacterial bronchitis. *Chest* 2014; 146: 1013-1020.
- Hodge S, Upham JW, Pizzutto SJ, *et al.* Is alveolar macrophage phagocytic dysfunction in children with protracted bacterial bronchitis a forerunner to bronchiectasis? *Chest* 2016; 149: 508-515.
- Chen AC, Pena OM, Nel HJ, *et al.* Airway cells from protracted bacterial bronchitis and bronchiectasis share similar gene expression profiles. *Pediatr Pulmonol* 2018; 53: 575-582.