



An unusual but important cause of wheezing

Case history

A 42-year-old Ecuadorian male presented with nocturnal wheezing, cough and purulent sputum. The symptoms had started approximately 4 months previously. After travelling to Venezuela, the patient had visited a general practitioner reporting flu-like symptoms which resolved with symptomatic medication. Soon afterwards, the patient developed dyspnoea with low-grade fever and eventually productive cough. The patient denied having had any other symptoms at that time. The patient was treated for community-acquired pneumonia with clarithromycin, acetylcysteine and bronchodilators. The symptoms improved, but nocturnal wheezing without dyspnoea and cough with purulent sputum had been bothering the patient intermittently during the previous 2 months. The cough was especially disturbing at awakening and at night. The patient self-referred to a pneumologist.

The patient had recently been diagnosed with COPD. His spirometry was described as a "mixed process characterised by a slight restrictive pattern and a mild-to-severe obstructive process" with post-bronchodilator improvement. The patient had a 25-pack-year smoking history, with cessation 3 years previously. The patient denied weight loss, current fever and any family history of cancer. A physical examination revealed a body mass index of 38 kg·m⁻², blood pressure 130/80 mmHg and pulse 88 beats·min⁻¹. On lung auscultation, prolonged exhalation and nocturnal wheezing was noticed. There were no other remarkable physical findings.

Laboratory studies revealed phosphocreatine elevation, but otherwise the results were normal. Chest radiography and computed tomography (CT) were carried out (figure 1).

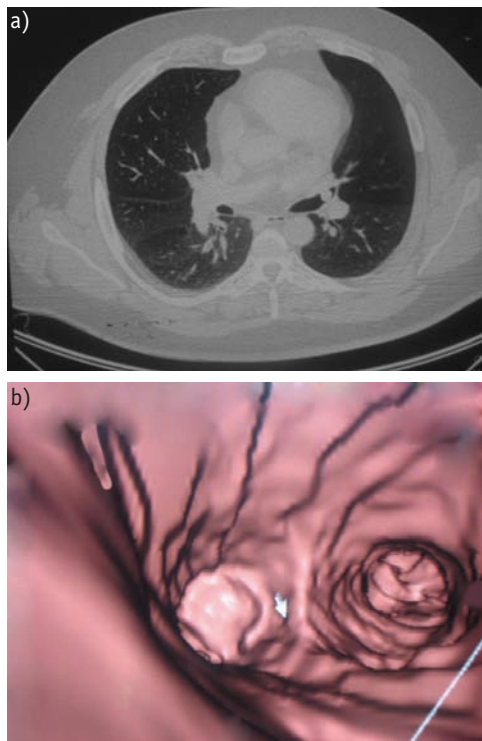


Figure 1
a) Chest CT scan. b) Corresponding computer reconstruction.

Task 1

How would you interpret the chest CT and tomographic reconstruction?

I. Cherez-Ojeda
A. Tafur
T. Guerrero
R. Mantilla

Instituto de Enfermedades
Respiratorias y Alergia,
Guayaquil, Ecuador.

Correspondence

I. Cherez-Ojeda
Hospital Clinica Kennedy
Av 9na Oeste y Av San Jorge
Guayaquil
Ecuador
Fax: 593 42288457
E-mail: icherrez@yahoo.com

Answer 1

A solid, smooth, partially obstructing 7-mm rounded hyperdense mass localised inside the left upper lobe bronchia is shown in both the CT scan and the reconstruction.

Based on the results of the CT, it was decided to perform a flexible bronchoscopy (figure 2). Bronchoscopy revealed a pink-coloured mass with a long pedicle connected to the internal wall of the left principal bronchus. The mass moved up and down as the patient breathed and its surface was smooth. Histology of the mass is shown in figure 3.

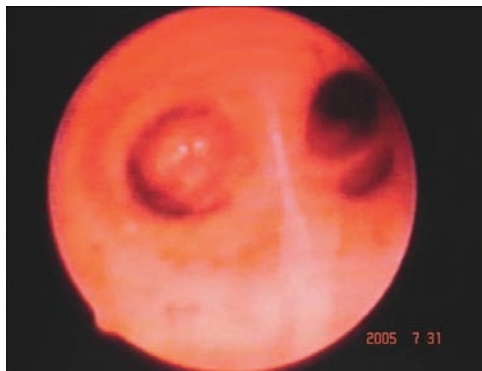

Figure 2
Picture taken during flexible bronchoscopy, showing a shiny, vascularised tumour.

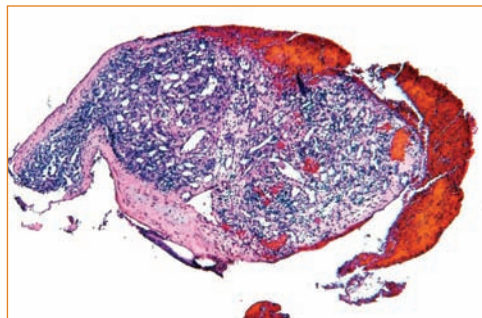


Figure 3
Histopathology of the bronchial tumour.

Answer 2

The figure shows a benign neoplastic proliferation of small capillaries and venules surrounded by endothelia. Mild mononuclear infiltrate and some haemorrhagic areas are also visible. The sample is compatible with a haemangioma.

Task 3

Suggest a treatment option for this patient.

Task 2

How would you diagnose this patient?

Answer 3

Surgical extirpation.

Clinical course

Although the current treatment of choice for such cases is bronchoscopic extirpation, this was unavailable locally, so the patient underwent open surgery. A half-lumen bronchotomy was carried out at the base of the tumour pedicle using an ultracision harmonic scalpel in order to avoid both a relapse and a caloric propagation wave that can produce muscle wall necrosis of the bronchus.

The patient recovered from the intervention and the symptoms were relieved completely.

Discussion

Although haemangiomas are the most common soft tissue tumour of infancy, they are very rare among adults [1–3]. Most tumours in the tracheobronchial tree are malignant, as demonstrated by SHAH *et al.* [4] in one of the largest series available. Only 1.9% of tumours in the series were benign, and of those only 10% (*i.e.* 0.19% of the total) were classified as angiomas.

Despite the benign and trivial nature of most cutaneous haemangiomas, airway haemangiomas are potentially life-threatening, as they may manifest with severe haemoptysis [2, 5]. The first of the few cases described in the literature was reported in 1978 by HARDING *et al.* [6], who presented a 67-year-old female whose left lower lobe bronchus was obstructed by the haemangioma. The lesion caused radiological signs (left lower lobe atelectasis) and it was removed at bronchoscopy. Cough, haemoptysis and stridor are the most common symptoms among reported

patients. Atelectasis is also often reported.

Although the pathogenesis of haemangiomas is not completely understood, it is known that rapid proliferation of endothelial cells is characteristic. As far as the location of these tumours is concerned, they very frequently compromise the skin, cervicofacial region and the upper respiratory tract [7]. While the diagnosis is usually suggested after bronchoscopy, dynamic contrast-enhanced CT is a valuable noninvasive method for the evaluation of airway haemangiomas [8]. It can be used to confirm the diagnosis in patients with equivocal findings on bronchoscopy, and some authors believe that CT findings are sufficiently specific to be recommended as the primary diagnostic method. As in the present case, a multiplanar reconstruction can help to illustrate the location, extent and degree of luminal narrowing. Because bronchoscopic findings of a submucosal tubular structure and visible pulsation are highly suggestive of endobronchial vascular lesion, extreme caution should be exercised in order to prevent fatal bleeding [9].

The currently recommended management for bronchial haemangiomas is a bronchoscopic procedure with either neodymium-doped yttrium aluminium garnet (Nd:YAG) laser or electrocoagulation. However, *en bloc* surgery has also been used in cases of profuse bleeding [7]. There is some data reporting the safety of cryotherapy during the procedure, but this is only preliminary [10].

Although they are unusual, bronchial haemangiomas should be considered among the causes of wheezing. The present case differs from those previously reported in that the main symptoms were initially compatible with pneumonia caused by the obstruction.

References

1. Drolet BA, Esterly NB, Freiden IJ. Hemangiomas in children. *N Engl J Med* 1999; 341: 173–181.
2. Watters K, O'Marcaigh A, Canny G, Russell J. Management of a large bronchial haemangioma in an infant. *Int J Pediatr Otorhinolaryngol* 2003; 67: 429–433.
3. Dinehart SM, Kincannon J, Geronemus R. Hemangiomas: evaluation and treatment. *Dermatol Surg* 2001; 27: 475–485.
4. Shah H, Garbe L, Nussbaum E, Dumon JF, Chiodera PL, Cavaliere S. Benign tumors of the tracheobronchial tree. Endoscopic characteristic and role of laser resection. *Chest* 1995; 107: 1744–1751.
5. Zhu L, Wang YQ, Li HC. Extirpation of bronchial hemangioma using bronchoscope: case report. *Chin Med J (Engl)* 2006; 119: 259–261.
6. Harding JR, Williams J, Seal RM. Pedunculated capillary haemangioma of the bronchus. *Br J Dis Chest* 1978; 72: 336–342.
7. Strausz J, Soltész I. Bronchial capillary hemangioma in adults. *Pathol Oncol Res* 1999; 5: 233–234.
8. Koplewitz BZ, Springer C, Slasky BS, et al. CT of hemangiomas of the upper airways in children. *AJR Am J Roentgenol*. 2005; 184: 663–670.
9. Park GY, Lee KY, Yoo CG, Kim YW, Han SK, Shim YS. Bronchoscopic findings of endobronchial vascular lesions in patients with haemoptysis. *Respirology* 1999; 4: 401–404.
10. Noppen M, Meysman M, Van Herreweghe R, Lamote J, D'Haese J, Vincken W. Bronchoscopic cryotherapy: preliminary experience. *Acta Clin Belg* 2001; 56: 73–77.