

P. Fazzi<sup>1</sup>  
R. Albertelli<sup>1</sup>  
M. Grana<sup>2</sup>  
P.L. Paggiaro<sup>1</sup>

<sup>1</sup>Cardio-Thoracic and Vascular Dept and <sup>2</sup>General Surgery and Transplantations, University of Pisa, Pisa, Italy

#### Correspondence

P. Fazzi  
Cardiothoracic and Vascular Dept  
Via Paradisa 2  
Cisanello Hospital  
56124 Pisa  
Italy  
Fax: 39 050995362  
E-mail:  
p.fazzi@dcap.med.unipi.it

#### Provenance

Commissioned article, peer reviewed

#### Competing interests

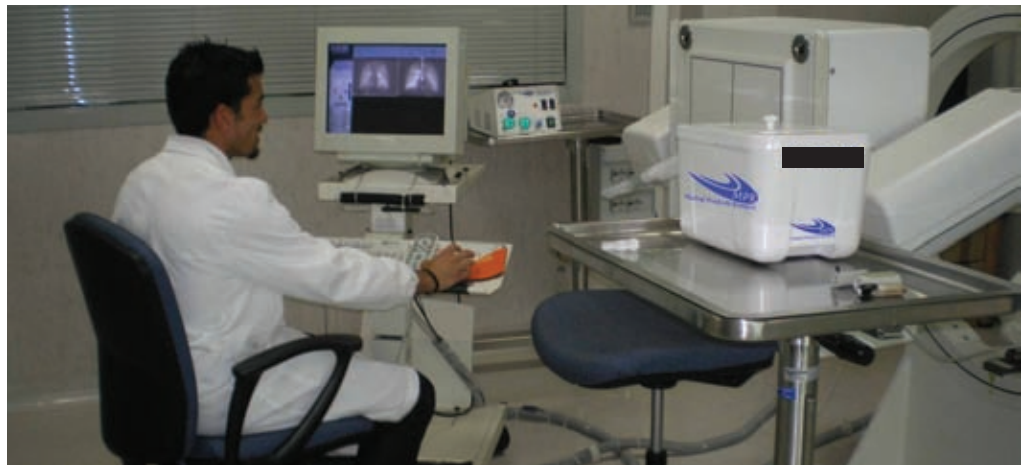None declared

#### Figure 1

Millennium MPR device (GE Medical Systems; GE Healthcare, Chalfont St Giles, UK).

HERMES syllabus link: modules D1.10, B1

# Lung ventilation scintigraphy in the assessment of obstructive lung diseases



## Educational aims

- › To describe more recent techniques used to study the regional distribution of ventilation.
- › To learn the most frequent abnormal patterns of lung ventilation scintigraphy (LVS) in obstructive lung diseases.
- › To compare the information obtained by this technique with that obtained by traditional lung function tests.
- › To understand that LVS may provide further information on lung pathophysiology.

## Summary

LVS is a well known technique that is used to study the distribution of ventilation in pulmonary diseases. However, its application in current practice has been poorly developed, mainly because of methodological problems. Redistribution of convective ventilation is the leading disorder in patients with chronic obstructive pulmonary disease (COPD) and is the target of most treatments, either by drugs or mechanical ventilation. The current availability of a new delivery inhaler (FAI; Medical Products Research, Legnano, Italy) with fine particles allows: 1) fast aerosol administration; 2) high-quality early images; 3) improved visualisation of pulmonary periphery; and 4) wider physiological distribution of the radioaerosol. Several patterns of distribution of pulmonary ventilation can be described in different airway disorders (asthma and COPD). These abnormalities are often too subtle to be picked up by traditional lung function tests, both in the baseline evaluation and after different interventions. Wider use of this technique may increase the knowledge and the management of obstructive lung diseases.

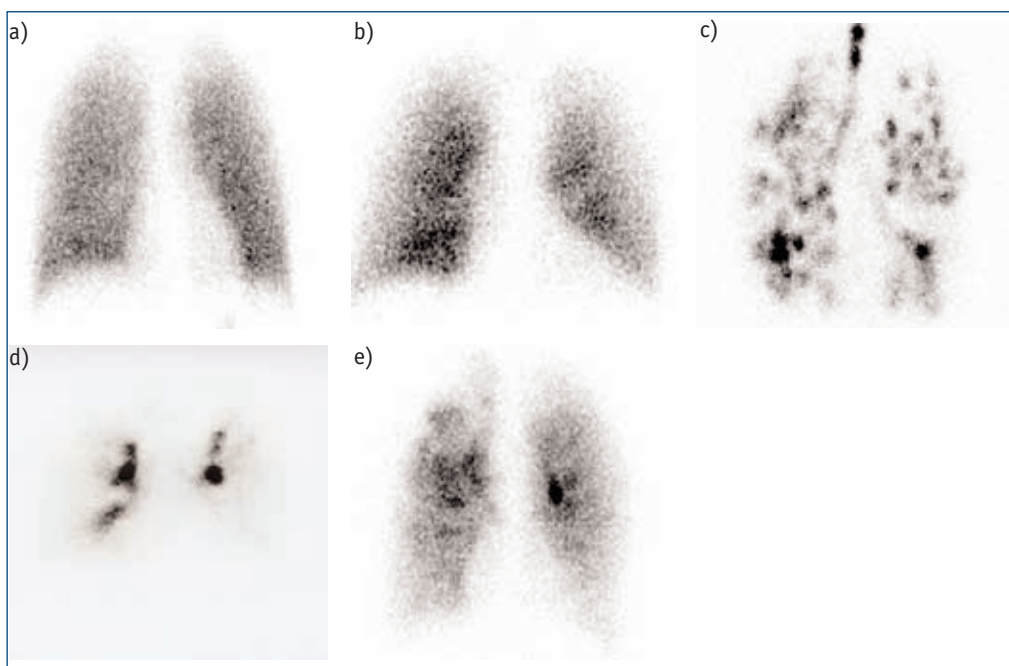
The regional distribution of lung ventilation represents a major physiological determinant of the efficiency of pulmonary gas exchange, together with the regional distribution of pulmonary flow (perfusion) and abnormalities of gas diffusion at the level of the alveolar capillary membrane [1]. Currently, there is considerable interest in studying one of the two major factors affecting the ventilation/perfusion ratio, often obtained by means of complex technologies (such as the multiple inert gas elimination technique [2]), both in normal subjects and in pulmonary disease patients. The regional distribution of ventilation has been studied in some pathological situations, for example in pulmonary embolism or in anatomical intrapulmonary shunt. In the first situation, pulmonary regions where ventilation is preserved and perfusion is lacking have been considered as proof of the presence of pulmonary embolism [3]. However, this point has not been confirmed in other studies [4]; therefore, the usefulness of adding ventilation to a perfusion scan is questionable. Conversely, nonventilated pulmonary regions with pulmonary flow may be considered as an indication of a consistent anatomical shunt [5].

This review aims to show the sensitivity of LVS, with respect to other more widely used lung function tests, in characterising patients affected by various obstructive lung diseases (such as asthma, chronic bronchitis and/or pulmonary emphysema), and in assessing the efficacy of treatment including mechanical ventilation.

Using a well-defined and standardised methodology, it is possible to demonstrate that this imaging technique may offer additional information to that provided by traditional lung function tests. In certain circumstances, LVS can provide improved physiological measurements, for example by showing functional impairment in many pathological lung conditions, as well as revealing the efficacy of pharmacological and nonpharmacological treatments.

## Methodological issues in studying the distribution of pulmonary ventilation

Inhaled radionuclide-labelled aerosols remain the most important clinical tool used to assess regional ventilation [6]. However, ROBERTSON [7] points out, according to earlier observations [8], that aerosol deposition on the large conducting airways can significantly impair evaluation of the regional distribution of ventilation in patients with severe airflow obstruction. ROBERTSON [7] suggests that this artefact can be minimised with the use of Technegas as the aerosol label, since the mean particle diameter is  $<0.01 \mu\text{m}$ ; aerosol particles at this size yield a higher fractional deposition due to enhanced motion by diffusion and are small enough to avoid impacting on airway walls [7]. A comparison of Technegas with  $^{133}\text{Xe}$  ventilation scans



**Figure 4**  
Ventilation patterns of deposition. a) Normal deposition, b) inhomogeneous deposition (ID), c) spotty deposition, d) central deposition (CD), e) mixed deposition (ID and CD).

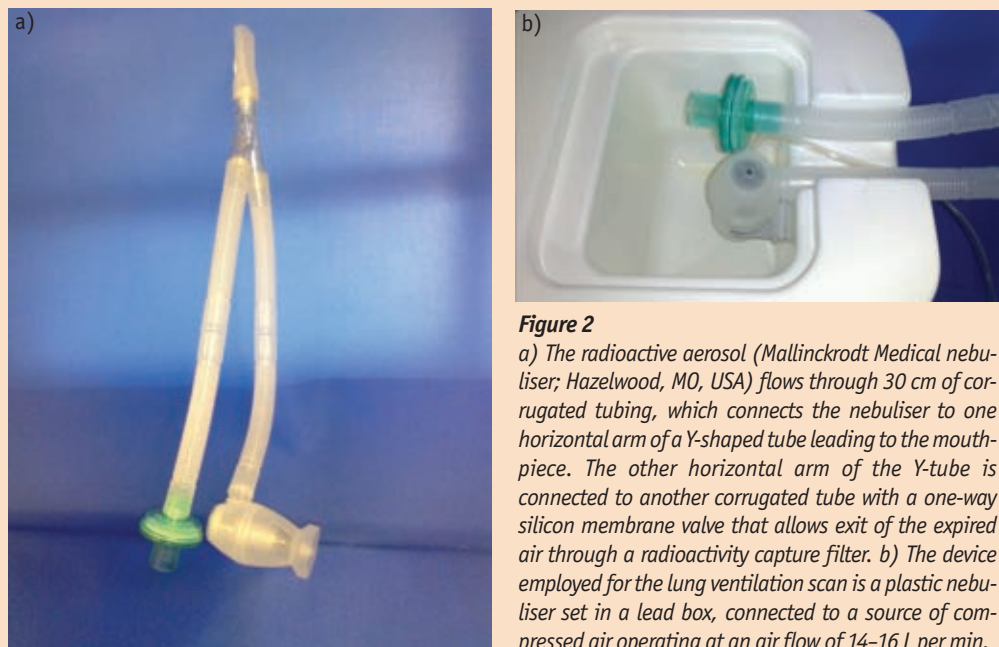
## Materials and methods for LVS using radionuclide-labelled aerosol particles and the FAI inhaler

**Radioactive particle aerosol**

Freshly eluted  $^{99m}\text{Tc}$ -pertechnetate (925 MBq in 3 mL physiological saline) is added to a vial containing lyophilised nanocolloidal albumin (Venticoll; GE Healthcare, Chalfont St Giles, UK) [25, 26], and stirred slowly for 5 min. It is then incubated for 15 min.

**FAI (Italian patent no. ITPI20020018)**

The commercial Mallinckrodt Medical inhaler (MMI; Mallinckrodt Medical, Hazelwood, MO, USA) is a plastic nebuliser set in a lead box connected to compressed air that operates at an air flow of 14–16 L per min and is used for the lung ventilation scan (figure 1). Upon inspiration, the radioactive aerosol produced by the nebuliser reaches the mouthpiece through 30 cm of corrugated plastic tubing. The radioactive aerosol produced by the FAI device uses the same nebuliser as the MMI (operating at 14–16 L per min) and flows through the same corrugated tubing that, in this inhaler, connects the MMI nebuliser to a Y-shaped tube (new inhaler device) leading to the mouthpiece (technical details are described elsewhere [27]; figure 1). The size and distribution of aerosol particles produced by the FAI system at the mouthpiece was measured using the Cascade Impactor (SKC Inc., Eighty Four, PA, USA). The FAI delivers droplets with a log-normally distributed diameter, a count median diameter of 1.4  $\mu\text{m}$  and a geometric SD of 2.0, with 80% of the particles in the range of 0.5 to 2  $\mu\text{m}$ , which are ideal for delivering drugs to (*i.e.* reaching) peripheral airways and alveoli [26]. However, according to BRAIN and VALBERG [28], some 20% of particles this size are deposited in the pulmonary region.



**Figure 2**

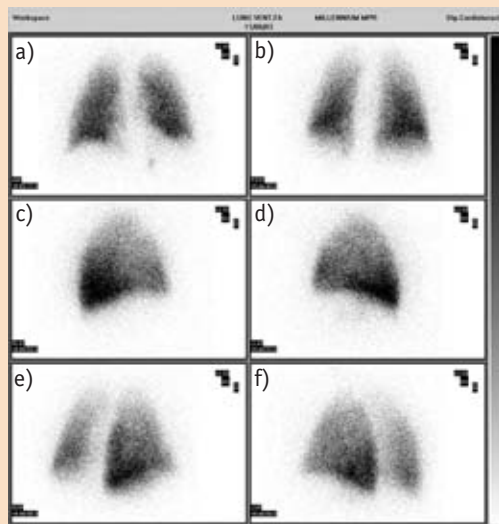
a) The radioactive aerosol (Mallinckrodt Medical nebuliser; Hazelwood, MO, USA) flows through 30 cm of corrugated tubing, which connects the nebuliser to one horizontal arm of a Y-shaped tube leading to the mouthpiece. The other horizontal arm of the Y-tube is connected to another corrugated tube with a one-way silicon membrane valve that allows exit of the expired air through a radioactivity capture filter. b) The device employed for the lung ventilation scan is a plastic nebuliser set in a lead box, connected to a source of compressed air operating at an air flow of 14–16 L per min.

**Lung ventilation scintigraphy**

While breathing the radioactive aerosol, the subject sits with his/her back positioned against the collimator face of a gamma camera equipped with a parallel-hole, high-resolution collimator (Millennium MPR; GE Medical Systems; figure 2). After setting a 10% window on the 140 keV emission peak of  $^{99m}\text{Tc}$ , a dynamic acquisition is performed (30 s per frame, 64×64 pixel matrix), which monitors count rate until it reaches 1 kc per s (time required to reach a certain count rate in the lung fields). At that point inhalation is stopped and static images in six planar projections (anterior, posterior, right and left lateral and right and left oblique-posterior) are obtained, recording 100,000 counts for each projection (256×256 matrix). The imaging protocol for the commercial device (MMI) also implies a delayed acquisition recorded at 3 h, because in the early images there is a

physiological accumulation of radioactivity in the large bronchial branches that could be mistakenly interpreted as a pathological CD pattern [10]. A pilot study, previously carried out in 50 subjects, showed that a similar pattern of CD was never observed in healthy subjects when using the FAI device, making delayed acquisition unnecessary [27, 29] (figure 3).

Patients are invited to rinse out their mouth and throat, in order to remove labelled particles deposited on the pharynx. Despite this procedure, physiological gastric activity of various degrees may be observed on scintigraphic images.



**Figure 3**

*A normal LVS in the six standard projections: a) anterior, b) posterior, c) right lateral, d) left lateral, e) right oblique-posterior and f) left oblique-posterior. Normal ventilation deposition consists of a uniform distribution of aerosol particles throughout the lung according to the physiological apex to base gradient, and at the clearly defined peripheral edges of both lungs.*

in patients with airflow obstruction showed no airway deposition of the aerosol despite the severe airflow obstruction of the subjects studied [9]. The problem with aerosol particles of this size is that they largely adhere to walls of the alveoli on inhalation and they have gas-like penetration characteristics [10]. For this reason, Technegas may not be suitable for the study of convective ventilation, whose distribution within the lung is determined by ventilatory mechanics [11].

The use of radioactive aerosols provides more detailed information on regional ventilation abnormalities caused by COPD [8, 10]. In particular, four specific patterns bearing a well-defined pathophysiological meaning have been identified in addition to the normal deposition (ND) pattern. These are the inhomogeneous deposition (ID) pattern, the central deposition (CD) pattern, the spotty deposition (SD) pattern and the mixed deposition (MD) pattern. These patterns cannot be seen in lung ventilation scans performed with gaseous tracers [8, 10–18].

Ventilation of the alveolar space is based on two main mechanisms: mass transport (convective ventilation) and molecular diffusion (diffusive ventilation). Convective flow takes inhaled gases only as far as the respiratory space close to the bronchioles, while the remaining air volume is renewed by molecular diffusion. Therefore, a ventilation lung scan performed with a gaseous

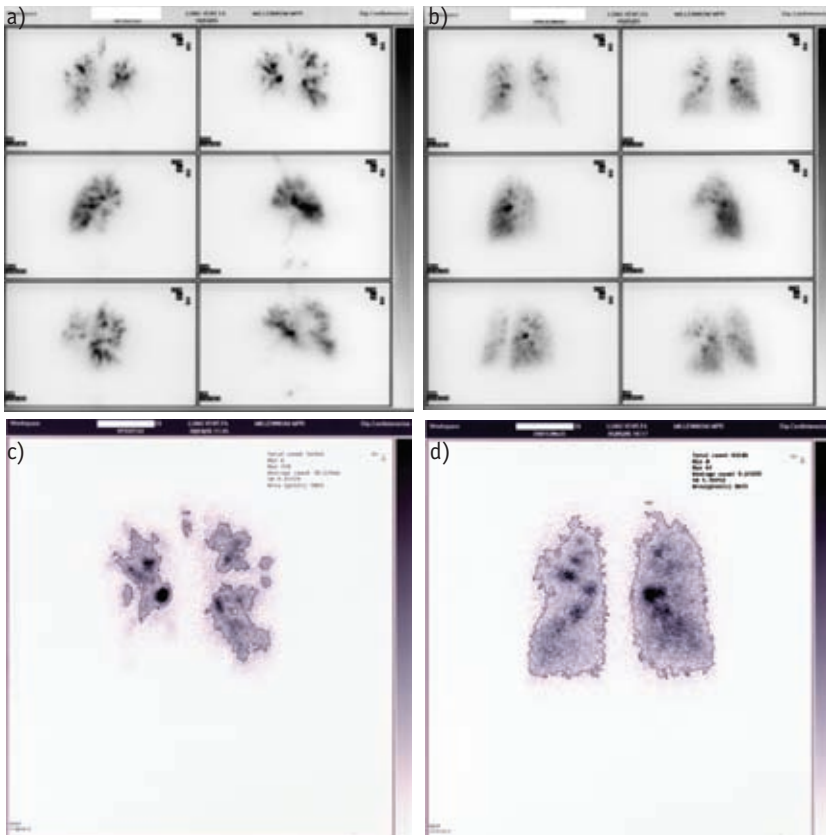
tracer yields a picture of the total air space in the lungs. Inhaled particles have a smaller diffusion capacity; thus, they are carried only by convective airflow and can be considered as tracers for mass transport (respiratory space up to the 21st-order bronchioles) [19, 20].

Furthermore, aerosol particles are much heavier than gas molecules; therefore, unlike gas molecules, some particles transported by airflow [21–24] settle in the peripheral respiratory elements through a mechanism of gravitational sedimentation [19, 21]. Since the proportion of small particles settling in the conductive airways (trachea and major bronchi) by inertial impact is very low [10, 19], lung ventilation scans performed with radioactive particles yield information mostly on convective ventilation. The volume where the particles distribute, defined as residual volume (RV), is very similar to the volume of the respiratory bronchioles [22–24].

## Qualitative evaluation of scintigraphic images

As previously described [10], qualitative evaluation of the ventilation lung scans consists of visual analysis of the intrapulmonary distribution of the inhaled radioactive aerosol, which allows for identification of the predominant pattern of deposition (figure 4).





**Figure 5**  
LVS (a and b) and C/pixels 10% threshold ROI (c and d) in acute asthma before (a and c) and after 5 days of treatment (b and d). c) Index of inhomogeneity 18.58 and d) index of inhomogeneity 9.61.

## Assessment of intra-pulmonary distribution of ventilation

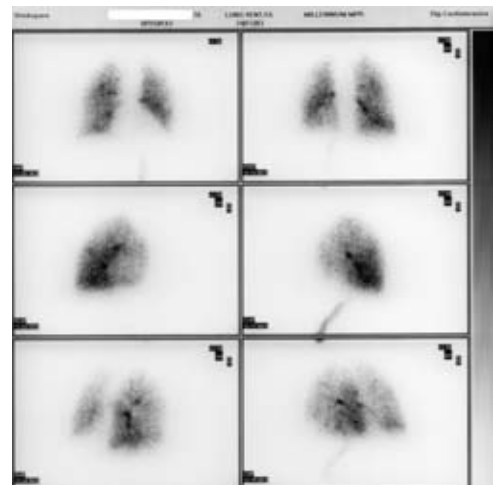
The loss of intraregional homogeneity in the distribution of ventilation can be semiquantitatively assessed on the basis of the "counts/pixel" (C/pixel) ratio, by applying the "automatic region of interest (ROI)" function of the Entegra software package (GE Healthcare). This function generates an ROI on the posterior projection of each lung field obtained during the ventilation scan, based on radioactivity count iso-profiles. A "30% threshold" ROI was created, defining the boundary of an area smaller than the whole organ. The mean C/pixel ratio is then derived within the "30% threshold" ROI. Healthy lungs are characterised by diffuse distribution of ventilation with a relatively low average C/pixel ratio (mean value in a large sample of subjects with normal lung function [10–12]); on the contrary, in lung disease, ventilation tends to be distributed to limited areas, with a consequent increase in the C/pixel ratio (figure 5). This ratio, which is directly proportional to the severity of the impairment in ventilation distribution, can be considered to represent a semiquantitative index of inhomogeneity of intrapulmonary ventilation [30].

By changing the activity threshold of the "automatic ROI" analysis from 30 to 10%, an area is defined that includes virtually all lung fields extending to the periphery (figure 5). This analysis is utilised to assess the extent of ventilated areas, expressed in pixels [31, 32].

**Figure 6**  
LVS pattern of a 70-year-old ex-smoker with chronic bronchitis. Blood gas analysis and pulmonary function test results were as follows. Forced vital capacity (FVC) 127% predicted; forced expiratory volume in 1 s (FEV<sub>1</sub>) 127% pred; FEV<sub>1</sub>/FVC ratio 89%; vital capacity 139% pred; total lung capacity 114% pred; and RV 107% pred.

The ND pattern is characterised by normal distribution of radioactivity in both lung fields with clearly defined peripheral lung edges and a physiological apex-to-base gradient. The ID pattern shows patchy areas in the peripheral regions of the lungs due to altered deposition of the particles, so that the peripheral pulmonary edges are irregular or incomplete. In the CD pattern, radioactivity is predominant in the hilar-parahilar region (*i.e.* close to the first or central bronchial generations), with an associated background of ID of ventilation. The SD pattern (which corresponds to the extreme degree of inhomogeneity for ID of the inhaled particles) is characterised by focal depositions of radioactivity (spots) within low-radioactivity count areas. Finally, the MD pattern shows intermediate features in the distribution of ventilation.

Although the most common five patterns of ventilation deposition are shown in figure 4, the CD that characterises the MD can be associated not only with an ID pattern but also with an SD pattern with a mixed pattern (CD and SD).



## Examples of clinical applications of LVS

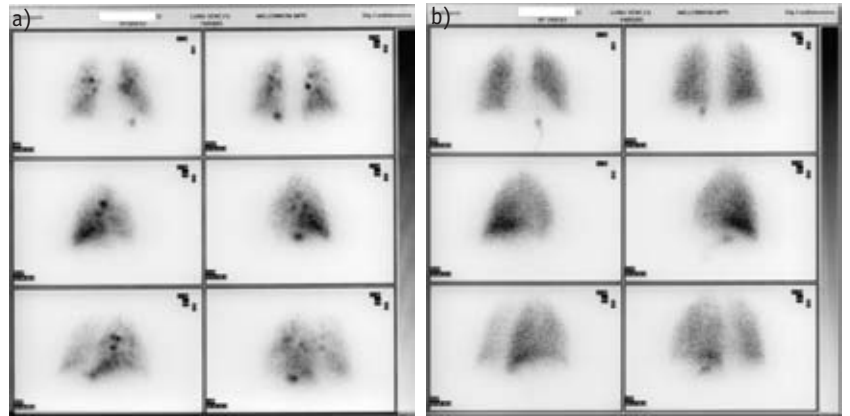
### Simple chronic bronchitis

Chronic bronchitis without airway obstruction ("simple chronic bronchitis") is believed to be an innocuous disease, with minor functional abnormalities and poor prognostic value. However, LVS may reveal significant impairment of the distribution of ventilation. Figure 6 shows the LVS pattern in a patient with chronic cough and phlegm, normal lung function tests but a clear abnormal mixed (CD, ID) ventilation pattern, which matches the presence of respiratory symptoms. The pattern of CD underlines the fact that, despite normal forced expiratory volume in 1 s (FEV<sub>1</sub>), airway resistance is increased, while the pattern of ID shows that this fact, together with the small airways involvement (poorly detected by traditional lung function tests), may affect the distribution of ventilation and peripheral gas exchange.

### Asthma

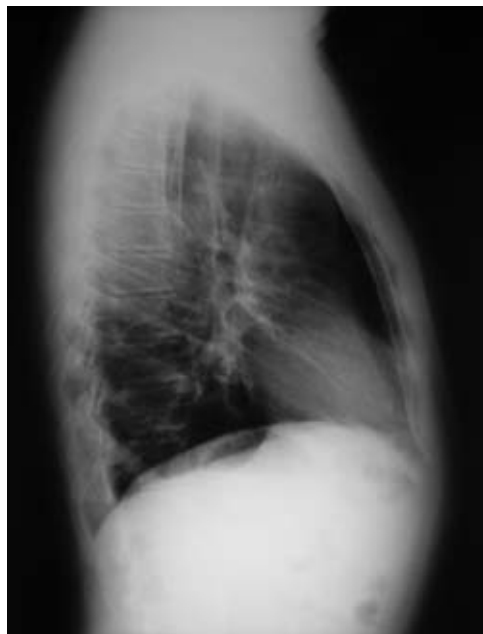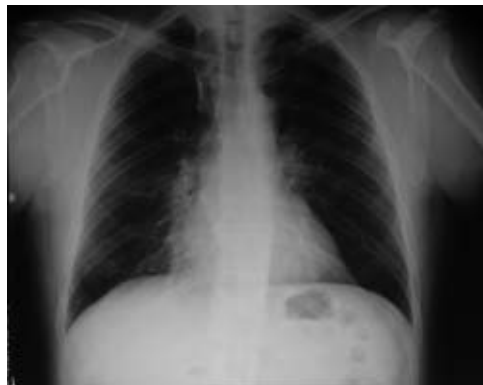Figure 7 shows LVS in a patient with a diagnosis of nonallergic asthma, observed in a stable phase of the disease. At baseline, although lung function tests were within the normal limit in this patient, the pattern of ventilation was abnormal, with a clear mixed (CD, ID) pattern, and the patient showed a significant improvement after 1 week of treatment with inhaled bronchodilators and corticosteroids. Moreover, FEV<sub>1</sub> improved in association with a great improvement in the distribution of ventilation in particular, CD was no longer observed and the distribution of ventilation in the lung periphery was more homogeneous. Therefore, in asthma, normal FEV<sub>1</sub> does not exclude the presence of lung function abnormalities, which may be susceptible to further improvement with treatment. This may also be due to the limitations of the currently available "reference" values for spirometry, which tend to underestimate the impairment of lung function.

In another patient with nonallergic asthma (figure 8), respiratory symptoms (persistent cough, phlegm and dyspnoea) were still present, in spite of regular treatment with low-dose inhaled corticosteroids; a chest radiograph showed the presence of some abnormalities (in particular, lung hyperinflation and reduction in peripheral vascular markings; figure 8). However, high-resolution computed tomography showed only minor signs of pulmonary emphysema and



**Figure 7**

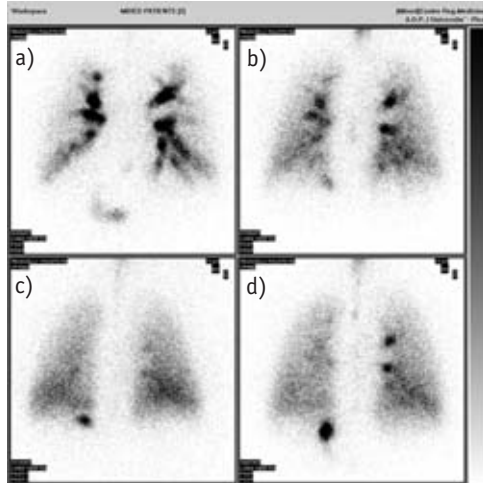
LVS pattern of a 31-year-old ex-smoker with nonallergic asthma at a) baseline (FEV<sub>1</sub> 104% pred) and b) after 1 week of inhaled therapy (FEV<sub>1</sub> 112% pred). Blood gas analysis and pulmonary function test results were as follows. FVC 114% pred; FEV<sub>1</sub> 104% pred; FEV<sub>1</sub>/FVC ratio 89%; vital capacity 123% pred; RV 93% pred; diffusing capacity of the lung for carbon monoxide 96%; and transfer coefficient of the lung for carbon monoxide 88%.



**Figure 8**

Two chest radiographs of a 53-year-old, ex-heavy smoker with nonallergic asthma.

**Figure 9**  
Posterior LVS patterns at a) baseline and b) 3 months, c) 6 months and d) 12 months after beginning treatment with high-dose inhaled corticosteroids and long-acting  $\beta_2$  agonists.

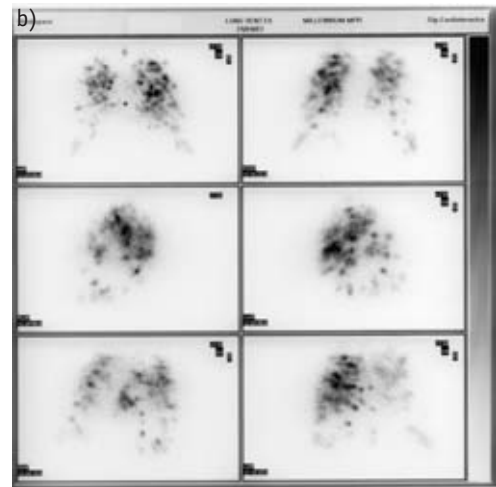
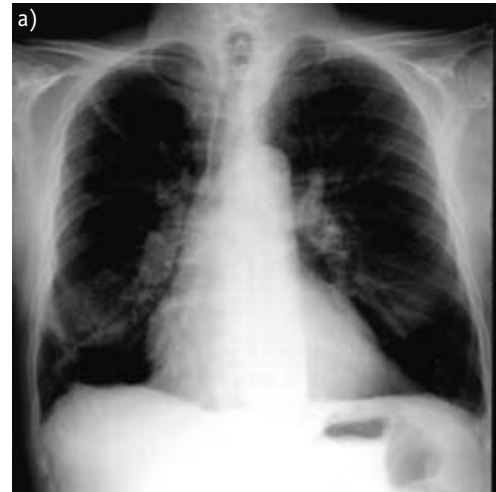


blood gas analysis and LVS. After 3 months, lung function tests were normal, and LVS was markedly improved, but still showed a CD pattern (figure 9b and table 1). In the following months, pulmonary function was maintained in the normal range, without any further improvement, while LVS progressively improved, showing an almost ND pattern (except for two areas of CD in the left lung) after 6 and 12 months of treatment (figure 9c and d and table 1).

This case supports the superior sensitivity of LVS in comparison with traditional lung function parameters, in monitoring the effect of treatment in asthma. Although this conclusion needs to be supported by a larger number of observations, the large changes in LVS over time in this subject, in association with a mild improvement in FEV<sub>1</sub>, suggest that lung ventilation pattern might offer further information to that obtained from traditional lung function tests.

**COPD**

In COPD, the distribution of lung ventilation is strongly affected by the severity of airway obstruction and the parenchymal damage due to emphysema. A mixture of SD, CD and ID may be



**Figure 10**  
a) Chest radiograph and b) LVS pattern from a 72-year-old COPD patient with hypercapnic respiratory failure. Blood gas analysis and pulmonary function test results were as follows. FVC 74% pred; FEV<sub>1</sub> 29% pred; FEV<sub>1</sub>/FVC ratio 30%; vital capacity 76% pred; RV 181% pred; FRC 177% pred; DL<sub>CO</sub> 38%; K<sub>CO</sub> 48%; pH 7.39; oxygen tension 71 mmHg; and carbon dioxide tension 42 mmHg. 1 mmHg = 0.133 kPa.

observed. The abnormality in regional lung ventilation may contribute to explain the pathophysiological abnormalities observed in these patients.

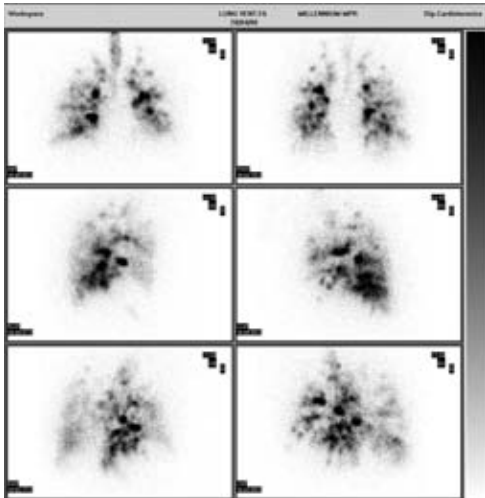
Figure 10 shows a patient with radiological signs of pulmonary emphysema (hyperinflation, reduction in vascular markers in lung periphery and enlargement of pulmonary vascular markings at the hila). The lung function tests confirm the presence of severe airway obstruction with an abnormal increase in RV and functional residual capacity (FRC), and a severe reduction in the diffusing capacity of the lung for carbon monoxide (DL<sub>CO</sub>) and transfer coefficient of the lung for carbon monoxide (K<sub>CO</sub>). The pattern of ventilation deposition is SD, reflecting an extreme degree of inhomogeneity distribution of aerosol particles in

**Table 1 Blood gas analysis and pulmonary function test results**

	Baseline	3 months	6 months	12 months
FVC % pred	86	91	89	92
FEV <sub>1</sub> % pred	73	95	90	94
FEV <sub>1</sub> /FVC %	83	93	94	94
DL <sub>CO</sub> %	73	83	84	88
pH	7.41	7.40	7.41	7.39
P <sub>a,O<sub>2</sub></sub> mmHg	84	83	93	96
P <sub>a,CO<sub>2</sub></sub> mmHg	39	40	40	38

DL<sub>CO</sub>: diffusing capacity of the lung for carbon monoxide; P<sub>a,O<sub>2</sub></sub>: arterial oxygen tension; P<sub>a,CO<sub>2</sub></sub>: arterial carbon dioxide tension. 1 mmHg = 0.133kPa.





**Figure 11**  
 LVS pattern of a 69-year-old ex-smoker with emphysema. Blood gas analysis and pulmonary function test results were as follows. FVC 119% pred; FEV<sub>1</sub> 54% pred; FEV<sub>1</sub>/FVC ratio 41%; VC 134% pred; RV 241% pred; FRC 230% pred; DL<sub>CO</sub> 77%; Kco 72%; pH 7.39; oxygen tension 71 mmHg; and carbon dioxide tension 42 mmHg. 1 mmHg = 0.133 kPa.

the lungs. Moreover, in this patient the gradient of ventilation distribution is inverted (base-apex and not apex-base). The pattern of SD associated with an inverted gradient of ventilation distribution justifies a severe impairment of gas exchange, more often characterised by hypercapnic respiratory failure.

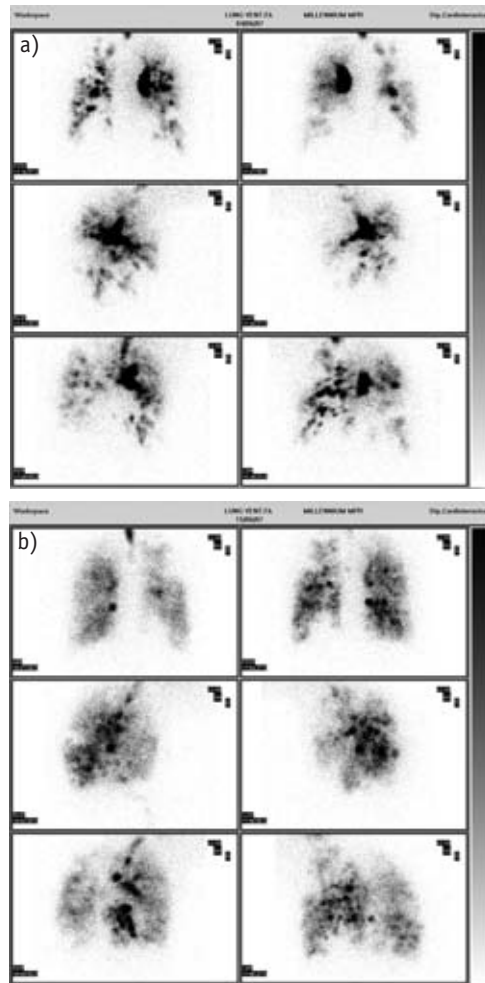
Figure 11 shows a different subject with pulmonary emphysema and moderate-to-severe airway obstruction, associated with an abnormal increase of static lung volumes (vital capacity (VC), RV and FRC) and a mild reduction of DL<sub>CO</sub> and Kco. LVS images show an MD pattern with several areas of "spotty ventilation"; however, the gradient of ventilation was maintained, which can contribute towards explaining the mild impairment of gas exchange.

Therefore, LVS may add further information to

**Table 1 Lung function analysis and blood gas analysis results**

	Baseline	1 week
FVC % pred	68	116
FEV <sub>1</sub> % pred	31	67
FEV <sub>1</sub> /FVC ratio %	44	56
pH	7.42	7.42
Pa <sub>a,O<sub>2</sub></sub>	53	69
Pa <sub>a,CO<sub>2</sub></sub>	44	43

Pa<sub>a,O<sub>2</sub></sub>: arterial oxygen tension; Pa<sub>a,CO<sub>2</sub></sub>: arterial carbon dioxide tension.



**Figure 12**  
 Pre-abdominal surgery LVS results a) at baseline and b) after 1 week of a reduction in smoking and treatment with high-dose inhaled corticosteroids and long-acting β<sub>2</sub> agonists for a 58-year-old heavy-smoking COPD patient.

the functional evaluation of COPD, in addition to that already obtained from the traditional lung function tests, and may contribute to characterising the different phenotypes of COPD.

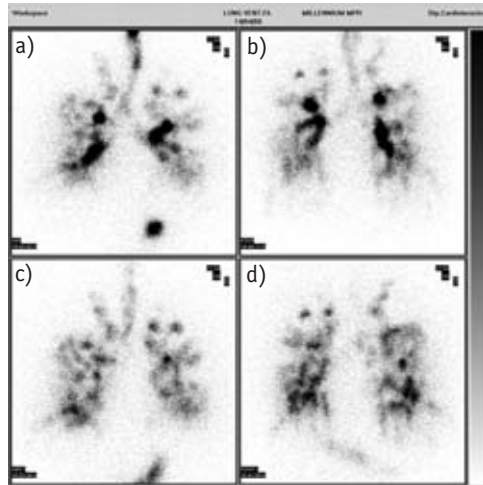
The efficacy of treatment during an acute exacerbation may also be documented by LVS. A 58-year-old heavy-smoking male patient who was a candidate for abdominal surgery was observed in pre-surgery evaluation during an acute exacerbation of COPD. Lung function tests and blood gas analysis documented the severity of the disease (figure 12 and table 2). A lung ventilation scan showed a severe abnormality of lung ventilation distribution, with a CD and SD pattern. The patient was treated with high-dose inhaled corticosteroids and long-acting β<sub>2</sub> agonists, and he also reduced his smoking habit. After 1 week, lung function and gas exchange were markedly improved, as was ventilation lung distribution in particular, the deposition of inhaled particles was more peripherally distributed and the CD was reduced.

Mucous plugging in the central and peripheral airways is a major problem in COPD patients, and several therapeutic strategies may be used to



**Figure 13**

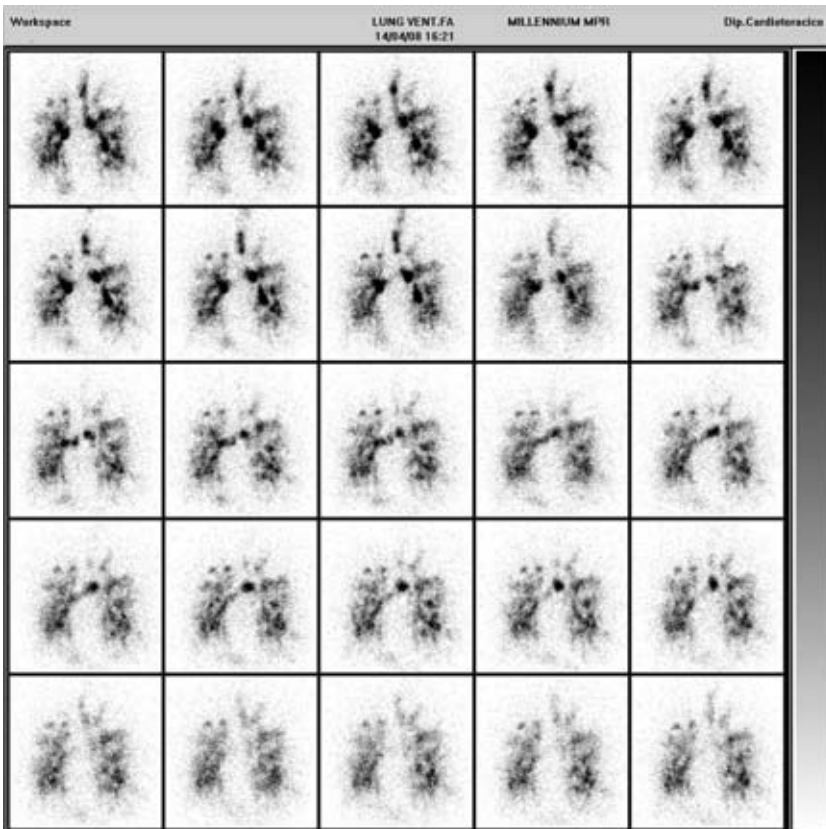
Anterior and posterior static LVS images before (a and c) and after (b and d) Uniko T-PEP (Medical Products Research, MPR, Legnano, Italy) treatment.



promote the removal of secretions from the airways. Both pharmacological and physiotherapeutic techniques are recognised as effective treatments. A new option may be to use minimal positive pressure ventilation to promote the progression of airway secretions from the lung periphery to the proximal airways. A new apparatus using this technique is the Uniko T-PEP (Medical Products Research, MPR, Legnano, Italy), which applies a minimal positive expiratory pressure (1 cmH<sub>2</sub>O (0.0977 kPa)) in the first two-thirds of the expiration, without any positive inspiratory support. This improves expiratory flow,

**Figure 14**

Dynamic ventilation for 12 min (1 frame per min) during Uniko T-PEP (Medical Products Research, MPR, Legnano, Italy) treatment.



allowing a better clearance of secretions from the airways.

Figure 13 shows the ventilation deposition pattern (CD, SD) in a patient affected by COPD (emphysema). The baseline CD pattern of ventilation deposition in the anterior and posterior projections (figure 13a) improves dramatically after 30 min of treatment with Uniko T-PEP, which induces an important discharge of airway secretions. LVS performed after Uniko T-PEP treatment (figure 13b) shows a marked reduction of central deposition, a significant trend to a more peripheral lung distribution of ventilation and a well-defined pattern (SD) of ventilation deposition, which is consistent with a diagnosis of emphysema.

The efficacy of this treatment may be better documented by the observation of the dynamic acquisition of ventilation in the posterior lung projection (2 frames per min for 30 min) during Uniko T-PEP (1 cmH<sub>2</sub>O (0.0977 kPa); figure 14). Figure 14 shows a continuous reduction until a complete disappearance of the CD after 10 min, confirming, in this patient, the efficacy of minimal Uniko T-PEP treatment on the discharge of airway secretions.

These last two patients consented to take part in a protocol concerning the study of regional distribution of ventilation and its modification under application of minimal Uniko T-PEP treatment in patients affected by COPD, before and after major abdominal surgery [33].

## Conclusions

LVS is a well-known technique for the assessment of the regional distribution of ventilation in normal subjects and in several pulmonary diseases. Despite the potential interest in studying this physiological measurement, the imaging technique has not been widely applied in current practice, mainly because of the many technical problems of the previous methodology. The use of a new delivery system of inhaled particles, combined with the characteristics of the radiolabelled particles, leads to the creation of an extra-fine aerosol, which may reach the lung periphery without any relevant deposition in the large airways in normal subjects. Using this new methodology, many artefacts that were observed with the older techniques (mainly due to excessive deposition in the large airways, which may mask the lung periphery) are overcome.

The description of the different patterns of lung deposition may be helpful to improve the

characterisation of obstructive lung disease. Despite these definitions, the sensitivity and specificity of the different ventilation scan patterns in comparison with the clinical diagnosis of airway disease (asthma *versus* chronic bronchitis *versus* emphysema) or with the chest tomography pattern (*e.g.* extent and localisation of emphysema) will require a large number of subjects. Preliminary observations from the present authors' laboratory suggest that the sensitivity of LVS for detecting abnormalities in subjects with

airway obstructive diseases is high (>90%). Also, the specificity of specific patterns of lung ventilation (such as CD or SD for asthma or emphysema, respectively) has been found to be high (Fazzi *et al.* unpublished observations).

Abnormalities in the pattern of lung deposition are more sensitive than changes in lung function tests and may be more sensitive to the effect of different treatments. Wider use of this technique may increase the knowledge and management of obstructive lung diseases.

#### References

- West JB. State of the art: ventilation-perfusion relationships. *Am Rev Respir Dis* 1977; 116: 919–943.
- Wagner PD, Laravuso RB, Uhl RR, West JB. Continuous distributions of ventilation-perfusion ratios in normal subjects breathing air and 100% O<sub>2</sub>. *J Clin Invest* 1974; 54: 54–68.
- The PIOPED investigators. Value of the ventilation/perfusion scan in acute pulmonary embolism: results of the prospective investigation of pulmonary embolism diagnosis (PIOPED). *JAMA* 1990; 263: 2753–2759.
- Sostman HD, Miniati M, Gottschalk A, Matta F, Stein PD, Pistoletti M. Sensitivity and specificity of perfusion scintigraphy combined with chest radiography for acute pulmonary embolism in Pioped II. *J Nucl Med* 2008; 49: 1741–1748.
- Wagner PD, Dantzker DR, Dueck R, Clausen JL, West JB. Ventilation-perfusion inequality in chronic obstructive pulmonary disease. *J Clin Invest* 1977; 59: 203–216.
- Anderson PJ, Dolowich MB. Aerosols as diagnostic tools. *J Aerosol Med* 1994; 7: 77–88.
- Robertson HT. Measurement of regional ventilation by aerosol deposition. In: Hlastala MP, Robertson HT, eds. Complexity in Structure and Function of the Lung. New York, Marcel Dekker Inc, 1998; pp. 379–399.
- Santolucando A, Ruschi S, Fornai E, Giuntini C. Imaging of ventilation in chronic obstructive pulmonary disease. *J Thorac Imag* 1986; 1: 36–53.
- Crowford ABH, Davison A, Annis TC, Engel LA. Intrapulmonary distribution of 99mTechnetium labelled ultrafine carbon aerosol (Technegas) in severe airway obstruction. *Eur Respir J* 1990; 3: 686–692.
- Santolucando A, Giuntini C. Patterns of deposition of labelled monodispersed aerosols in obstructive lung disease. *J Nucl Med Allied Sci* 1979; 23: 115–127.
- Hayes M, Taplin GV. Lung imaging with radioaerosols for the assessment of airway disease. *Semin Nucl Med* 1980; 10: 243–251.
- Effros RM, Mason GR, Mena I. 99mTc-DTPA aerosol deposition and clearance in COPD, interstitial disease, and smokers. *J Thorac Imaging* 1986; 1: 54–60.
- Maini CL, Bonetti MG, Giordano A, *et al.* Scintigraphy of pulmonary ventilation with 99mTc-DTPA radio-aerosol. I. Semiotics of the static images. *Radiol Med* 1986; 72: 204–209.
- Loken MK, Westgate HD. Using 133Xe and a scintillation camera to evaluate pulmonary function. *J Nucl Med* 1968; 9: 45–49.
- Mishkin FS, Brashear ER, Reese IC. Evaluation of regional perfusion and ventilation using <sup>133</sup>Xe and the scintillation camera. *Am J Roentgenol Radium Ther Nucl Med* 1970; 108: 60–70.
- Fazio F, Jones T. Assessment of regional ventilation by continuous inhalation of radioactive Krypton-81m. *BMJ* 1975; 3: 673–676.
- Fazio F, Wollmer P, Lavender JP, Barr MM. Clinical ventilation imaging with In-113m aerosol: a comparison with Kr-81m. *J Nucl Med* 1982; 23: 306–314.
- Agnew JE, Wood EJ, Sutton PP, Bateman JR, Pavia D, Clarke SW. Krypton-81m and 5-micron radioaerosol images in asymptomatic asthma: a blind marking assessment. *Eur J Nucl Med* 1984; 9: 502–507.
- Landahl HD. On the removal of air-borne droplets from the human respiratory tract: I. The lung. *Bull Math Biophysics* 1950; 12: 43–56.
- Weibel ER. Morphometry of the Human Lung. Berlin, Gottingen, Heidelberg, Springer, 1965; p. 139.
- Stuart BO, Wash R. Deposition of inhaled aerosols. *Arch Intern Med* 1973; 131: 60–72.
- Altshuler B, Palmes ED, Yarmus L, Nelson N. Intrapulmonary mixing of gases studied with aerosols. *J Appl Physiol* 1959; 14: 321–327.
- Cumming G, Horsfield K, Jones JC, Muir DC. The influence of gaseous diffusion on the alveolar plateau at different lung volumes. *Resp Physiol* 1967; 2: 386–398.
- Morrow PE. Conference on the scientific basis of respiratory therapy. Aerosol therapy. Aerosol characterization and deposition. *Am Rev Respir Dis* 1974; 110: 88–99.
- De Schrijver M, Streule K, Senekopwitsch R, Fridrich R. Scintigraphy of inflammation with nanometer-sized colloidal tracers. *Nucl Med Commun* 1987; 8: 895–908.
- Ballinger JR, Andrey TW, Boxen I, Zhang ZM. Formulation of technetium-99m aerosol colloid with improved delivery efficiency for lung ventilation imaging. *J Nucl Med* 1993; 34: 268–271.
- Fazzi P, Borsò E, Albertelli R, Mariani G, Giuntini C. Comparative performance of two inhaler systems to assess the distribution of convective ventilation by 99m Tc-labeled aerosol in patients with airway obstruction. *Q J Nucl Med* 2008 [Epub ahead of print. PMID: 19174757].
- Brain JD, Valberg PA. State of the Art. Deposition of aerosol in the respiratory tract. *Am Rev Respir Dis* 1979; 120: 1325–1373.
- Fazzi P, Borsò E, Albertelli R, *et al.* Regional ventilation with a 99mTc-nanocolloidal aerosol and perfusion lung scans *versus* lung function tests by testing a new ventilation equipment. *Q J Nucl Med* 2002; 46: Suppl. 1, 90.

#### Educational questions

Are the following statements true or false?

- LVS is a more sensitive technique compared with lung function tests.
- LVS is an invasive test that is difficult to perform on patients with respiratory failure.
- Patterns of ventilation deposition do not show diagnostic specificity.
- LVS results in a high absorbed radiation dose.
- The interval of time between LVS at baseline and controls must be ~1 week.

30. Kaneta T, Yamazaki T, Maruoka S, *et al.* Correlation of pulmonary perfusion volume analysis with pulmonary function in emphysema. *Kaku Igaku* 2000; 37: 359–364.
31. Uchida K, Miyasaka T, Nakayama H, *et al.* An application of semiquantitative analysis of pulmonary scintigram to tuberculosis sequelae. *Kaku Igaku* 1996; 33: 753–757.
32. Uchida K, Nakayama H, Yamagami I, Takahashi H, Takano M. Correlation of semiquantitative analysis of the distribution of pulmonary perfusion with pulmonary function in chronic obstructive pulmonary disease. *Kaku Igaku* 1997; 34: 145–149.
33. Fazzi P, Girolami G, Albertelli R, Grana M, Mosca F, Giuntini C. IPPB with temporary expiratory pressure (T-PEP) in surgical patients with COPD. *Eur Respir J* 2007; 30: Suppl. 51, P1980.

## ERS School course: Medical aerosols

In collaboration with the International Society for Aerosol Medicine, the ERS will organize a 3-day course on Medical Aerosols: Ins and Outs of Inhalation Therapy in Amsterdam (Netherlands), from November 12–14, 2009. The course will provide state-of-the art knowledge of basic aerosol science needed to deliver optimal clinical care, New nebuliser technologies, key issues of treating diseased airways, paediatric and adult aspects of aerosol medicine, and much more. It will include lectures in the morning and a wide range of workshops in the afternoon. Programme and registration are available at: [www.ersnet.org/schoolcourses](http://www.ersnet.org/schoolcourses)



Suggested answers

1. True.
2. False.
3. False.
4. False.
5. False.