

# Unusual dyspnoea



A 22-year-old female student presented at the Diagnostic Center "IKEDA" (Tirana, Albania) with a 1-year history of progressive dyspnoea. She had significant stridor, but no hoarseness. Her medical history did not reveal any significant disease, except the fact that she had been treated for the whole of the previous year for bronchial asthma. The treatment had included  $\beta_2$ -agonists and

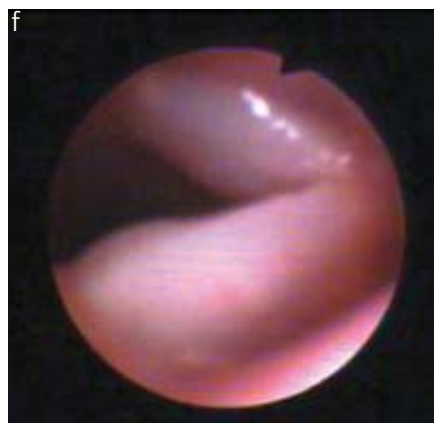
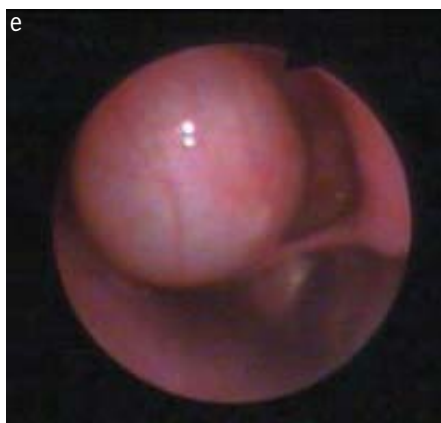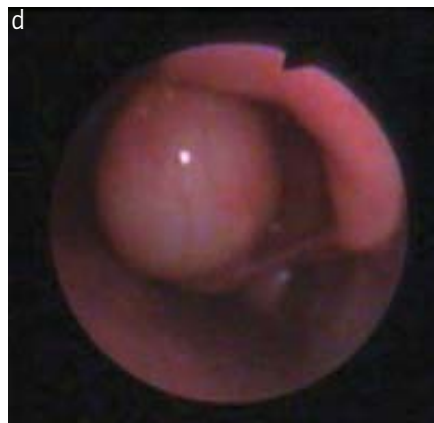
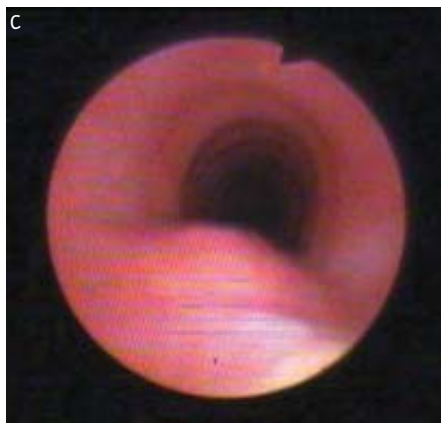
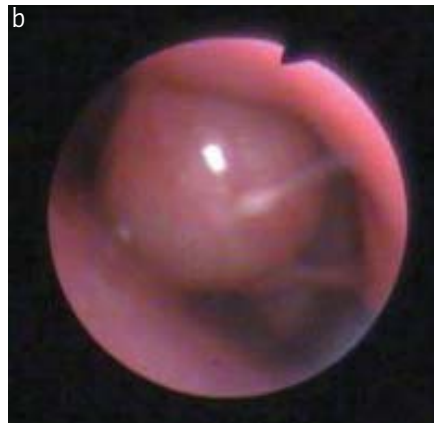
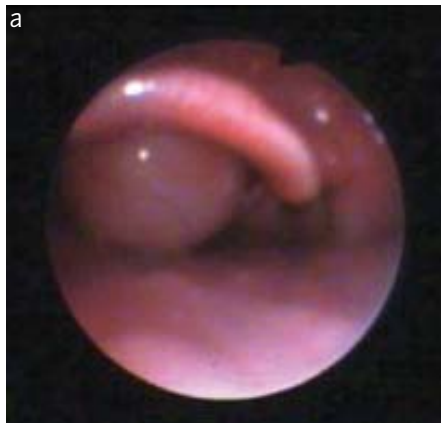inhaled and systemic corticosteroids. The treatment was not effective. The patient did not smoke. There was no palpable mass in the neck, and radiography of the chest was normal. A flexible fiberoptic examination was performed and this suggested expansion of the left aryepiglottic fold in a saccular shape.

M. Ibro  
I. Peposhi  
J. Bulaj

Diagnostic Center "IKEDA",  
Tirana, Albania.

## Correspondence:

M. Ibro  
Rruga "Kongresi" I Manastirit  
19/3  
00355 Tirana  
Albania  
Fax: 355 4365817  
E-mail: mustafaibro@yahoo.com



**Task 1**  
View the images  
presented and suggest  
a possible diagnosis.

**Answer 1**

The diagnosis of **saccular cyst of larynx** was considered.

Subsequently, a 2-mm computed tomography (CT) scan was obtained. The CT scan confirmed the presence of a large cyst arising from the laryngeal ventricle with minimal extension through the thyrohyoid membrane, but with a significant supraglottic obstruction of the airways. The vocal cords were normal. The treatment selected was endoscopic laser marsupialisation. Tracheotomy was not performed. Follow-up fibre-optic laryngoscopy 2 weeks after surgery showed some residual redundant mucosa prolapsing from the ventricle. Some 6 months after surgery the patient was well.

The final diagnosis for this patient was indeed saccular cyst of the larynx.

**Discussion**

Saccular cyst of the larynx is an uncommon benign cyst. The origin of laryngeal cysts is thought to be congenital or acquired. They can be the result of prolonged intubation, laryngeal surgery or laryngoscleroma. A saccular cyst is thought to result either from atresia of the orifice

of the laryngeal saccule, or from retention of mucus in the collecting ducts of submucosal glands located around the ventricle. The lesions are classified as anterior or lateral according to their location.

The airway compromise caused by these lesions may be severe, and in one series reported [1], ~50% of the cases were diagnosed at biopsy. The importance of early recognition should be emphasised, and diagnosis has been facilitated by advances in flexible fibreoptic technology, which allows the examination of even very small infants at the bedside. Several modalities of treatment have been advocated. These range from repeated needle aspiration, mainly as an adjunct to preserve the airways, to endoscopic laser marsupialisation, and to the transthyrohyoid membrane approach that was used in this case. The literature suggests that patients with larger cysts are best treated *via* an external approach because endoscopic treatment of larger lesions has resulted in a recurrence rate of 22% [2].

In conclusion, the saccular cyst is an uncommon congenital anomaly of the larynx that should be suspected in neonatal airway obstruction of immediate onset. Diagnosis is aided by the newest generation of fibreoptic endoscopes and rapid-acquisition CT scans. Smaller lesions may be treated endoscopically, whereas larger cysts are likely to require an external approach.

**References**

1. Ward RF, Jones J, Arnold JA. Surgical management of congenital saccular cysts of the larynx. *Ann Otol Rhinol Laryngol* 1995; 104: 707–710.
2. Thabet MH, Kotob K. Lateral saccular cyst of the larynx. Aetiology, diagnosis and management. *Laryngol Otol* 2001; 115: 293–297.
3. Wansa SA, Jones NS, Watkinson J. Unusual laryngeal cyst. *J Laryngol Otol* 1990; 104: 145–146.
4. Shandilay M, Coleeavy MP, Hughes J, et al. Endolaryngeal cyst presenting with acute respiratory distress. *Clin Otolaryngol Allied Sci* 2004; 29: 492–496.

**Editorial comment**

This Case presentation reflects the often-cited problem: “all that wheezes is not asthma”. This young student had suffered from increasing dyspnoea for 1 year and she had received inhaled steroids, as well as systemic steroids and inhaled  $\beta_2$ -agonists, without effect. This Case presentation underlines the importance of following patients set upon treatment for a chronic disorder. In one way, the treatment can be looked upon as part of the continuing diagnostic process. If, as in this case, the treatment is not effective, an explanation should be sought. Flexible bronchoscopy gave the diagnosis of a saccular laryngeal cyst, as seen from the illustrative and beautiful photographs obtained through the bronchoscope, and the cyst was eventually treated surgically with success.

Perhaps, *via* careful examination by the referring physician, an alternative diagnosis to asthma could have been suspected earlier. Stridor by laryngeal causes is usually inspiratory, whereas the dyspnoea caused by asthma is usually expiratory. Furthermore, the maximum expiratory and inspiratory flow-volume curve often demonstrates a distinct pattern with extrathoracic airways obstruction. Both the expiratory and the inspiratory parts of the flow-volume curve are often flattened. Whether the flow-volume curve in this case would have been a help in the diagnosis is not known, but it is a reminder to us to employ flow-volume curves as part of the examination of patients with asthma, as well as in other respiratory disorders.