

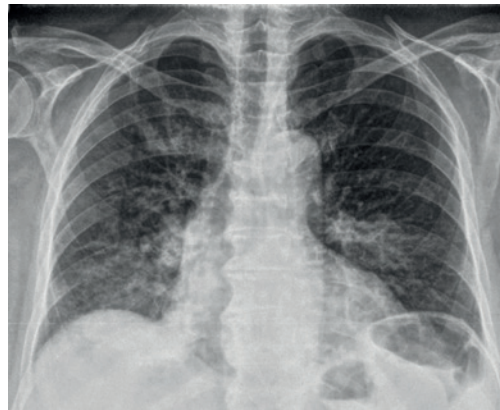## Case report

# An unusual disease with an interesting sign

### Case report

A 78-year-old male presented at the emergency room complaining of dry cough, fever up to 38.5 °C and malaise for 1 month. He had visited a general practitioner and received amoxicillin 500 mg three times a day for 7 days for a presumed chest infection, without improvement. He had a history of diabetes and arterial blood hypertension, for which he was receiving metformin 1000 mg twice a day and amlodipine 10 mg a day for 7 years. He reported no alcohol abuse and was an ex-smoker of 20 pack-years (quit 30 years ago). He had no recent hospitalisations or any medical interventions.

Physical examination revealed a patient who was febrile (37.8 °C) and in a mildly lethargic condition; however, he was fully orientated. Arterial blood pressure was 115/75 mmHg, heart rate was 85 beats·min<sup>-1</sup>, respiratory rate was 20 breathes·min<sup>-1</sup> and oxygen saturation was 92%. Arterial blood gases showed partial oxygen pressure 67 mmHg, CO<sub>2</sub> 32 mmHg and pH 7.43. He had diffuse crackles over mid- and lower-lung fields bilaterally. Laboratory tests revealed elevated white blood cell counts (12 800 cells per µL) of neutrophilic type (78%), erythrocyte sedimentation rate 85 mm·h<sup>-1</sup> and C-reactive protein 8 mg·dL<sup>-1</sup>. Kidney, liver and rest biochemistry was normal. The patient then had a chest radiograph performed (figure 1).



**Figure 1** Chest radiography showing pulmonary infiltrates with air bronchogram in mid- and lower-lung fields bilaterally.

#### Task 1

What is your differential diagnosis?

- Community-acquired pneumonia
- Aspiration pneumonia
- Interstitial pneumonia
- Pulmonary embolism

**Cite as:** Afthinos A, Antonakis E, Horti M, *et al.* An unusual disease with an interesting sign. *Breathe* 2020; 16: 190302.

@ERSpublications

**Acute interstitial pneumonias mimic infectious pneumonias. Radiology signs point to, but usually don't establish, diagnosis.** <http://bit.ly/3b3P1iK>



CrossMark



© ERS 2020

**Answer 1**

Due to the indolent subacute disease, mildly lethargic condition, advanced age and radiograph findings bilaterally in lung bases, we considered aspiration pneumonia (b) as a possible diagnosis. However, interstitial pneumonia was considered likely after ruling out infectious causes for the condition. No risk factors for pulmonary embolism (d) were present.

**Task 2**

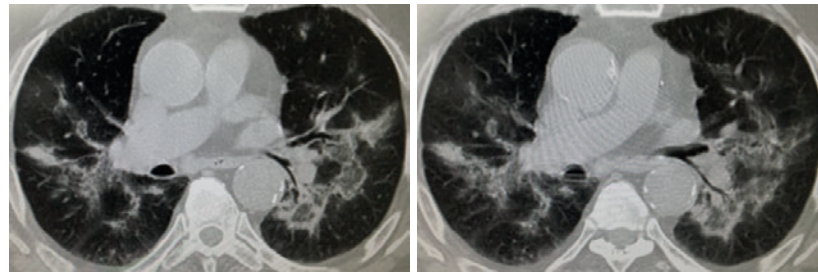
What would you do next?

- a) Start antibiotics
- b) Order a computed tomography (CT) scan
- c) Perform bronchoscopy
- d) Start corticosteroids

**Answer 2**

a and b. The patient was started on ampicillin-sulbactam plus azithromycin (a). Broad-spectrum antibiotics accounting for likely aspiration pneumonia are necessary at this point of evaluation. A CT scan was then ordered. Corticosteroids had no indication and bronchoscopy could follow depending on clinical outcome and CT results.

The patient was started on antibiotics without clinical or laboratory improvement and a high-resolution CT (HRCT) scan was performed (figure 2).



**Figure 2** HRCT scan of the lungs, showing diffuse parenchymal disease.

**Task 3**

Can you describe the findings on the HRCT scan?

**Answer 3**

Increased lung attenuation opacities bilaterally, right upper lobe, right lower lobe, left upper lobe and left lower lobe in the form of ground-glass opacities and dense consolidation. Typical reverse halo sign is noted especially in the left lower lobe. Reverse halo sign constitutes of a ground-glass opacity surrounded by a dense consolidation. A mild right pleural effusion is noted.

**Task 4**

What is your differential diagnosis based on the results of the HRCT scan?

- Cryptogenic organising pneumonia (COP)
- Typical or atypical pulmonary infection (fungi and parasites)
- Pulmonary haemorrhage
- Lung cancer
- Granulomatosis with polyangiitis

**Answer 4**

All the above differential diagnoses may be causes of a reverse halo sign on a HRCT scan. Options b and c were considered unlikely since the patient had no risk factors (underlying or pharmaceutical immunosuppression) for opportunistic infections, no haemoptysis and no drop in haematocrit levels. No evidence of systemic or upper respiratory system vasculitis existed either (e). COP and lepidic growth pulmonary neoplasms were considered the most likely diagnoses.

Blood and sputum cultures were negative for bacteria and urine antigen tests for *Streptococcus pneumoniae* and *Legionella pneumophila* serogroup I were all negative. Serum immunology sent for testing of antinuclear antibodies, antineutrophil cytoplasmic antibodies and anti-cyclic citrullinated peptide antibodies were all negative.

**Task 5**

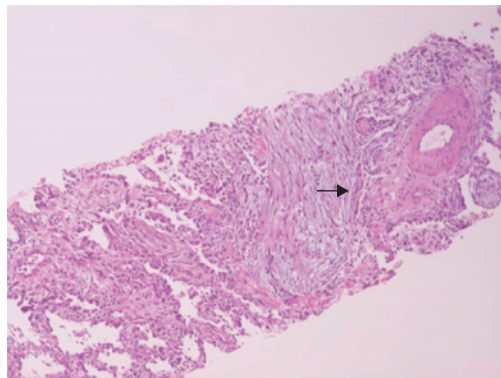
The patient is non-responsive to antibiotics, remaining febrile with elevated serum inflammation markers. What would you do next?

- Obtain a lung biopsy with video-assisted thoracoscopic surgery
- Wait and see
- Bronchoscopy with protected specimen brush
- Bronchoscopy with bronchoalveolar lavage (BAL) and transbronchial lung biopsy

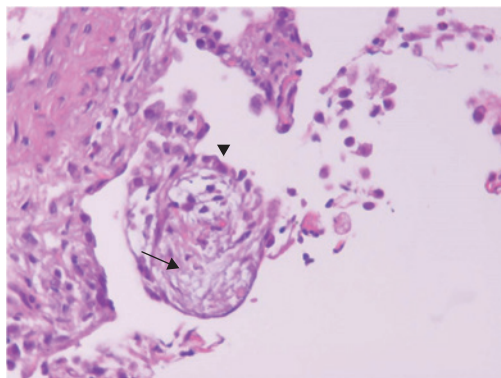
**Answer 5**

d. Bronchoscopy with BAL and transbronchial lung biopsy. Since we suspect diseases (like cryptogenic organising pneumonia) that may affect the small airways and pulmonary parenchyma, biopsy *via* bronchoscopy as a first step is always more preferential than interventional surgery techniques. Protected specimen brush is of value when we suspect opportunistic infections mainly in patients with haematologic malignancies. The wait and see approach is often useful; but in our case, as the likelihood of noninfectious aetiologies arises, alternate diagnosis establishment should be directly pursued.

A bronchoscopy was then performed 3 days after the patient's original admission. Apart from diffusely erythematous mucosa, no focal findings were seen on direct visualisation. BAL was performed at lingula and transbronchial lung biopsy (TBLB) was performed at the basal segments of the lower left lobe. BAL was negative for malignancy and cultures were negative for bacteria, nocardia, fungi and mycobacteria. BAL had increased cellularity,  $26 \times 10^6$  total cells and a mixed cellularity pattern, with neutrophils accounting for 12%, eosinophils 8%, lymphocytes 16% and macrophages 64%. Perls, Oil Red O and Periodic acid-Schiff stains were all negative. TBLB findings are shown in figures 3 and 4.



**Figure 3** Fibromyxoid plugs of granulation tissue in the distal airways (arrow). Haematoxylin eosin stain. Magnification  $\times 100$ .



**Figure 4** Intra-alveolar loose connective tissue plug (arrow) with a ring of type II pneumocytes (arrowhead). Histology pattern of organising pneumonia with accompanying bronchiolitis obliterans. Haematoxylin eosin stain. Magnification  $\times 200$ .

### Task 6

What is the diagnosis?

### Answer 6

COP.

Organising pneumonia may be secondary to infections, autoimmune diseases, drug toxicities, various lung injuries, thyroid diseases and malignancies. Since no such conditions were present and were reasonably excluded, we considered a diagnosis of COP. Antibiotics were ceased, a tuberculin sensitivity test was performed (negative) and the patient was started on prednisone 20 mg a day. He showed immediate response as fever subsided, as did blood inflammatory markers (erythrocyte sedimentation rate  $45 \text{ mm}\cdot\text{h}^{-1}$  and C-reactive protein  $2 \text{ mg}\cdot\text{dL}^{-1}$ ) and the patient was discharged home after 5 days on prednisone. His instructions were to taper off corticosteroids for a total duration of treatment of 6–12 months. Following complete clinical and radiological resolution of his disease, he has had no evidence of recurrence at follow-up visits.

## Discussion

COP is one of the major idiopathic interstitial pneumonias sub-categorized at acute/subacute interstitial pneumonias, according to the latest American Thoracic Society/European Respiratory Society classification of idiopathic interstitial pneumonias in 2013 [1]. COP corresponds to the radiological/morphological and pathology pattern of organising pneumonia. Organising pneumonia may be secondary to many aetiologies such as infections, drug reactions, malignancies, other interstitial pneumonias and autoimmune diseases (table 1). When secondary causes of

**Table 1** Causes of secondary organising pneumonia

### Drug toxicity

- Amiodarone
- Minocyclin
- $\beta$ -blockers
- Beomycin
- Carbamazepine
- Mesalamine
- Penicillamine

### Chronic thyroiditis

### Common variable immunodeficiency

### Infections

- Bacterial, fungal, viral

### Haematologic malignancies

- Lymphoma, leukaemia

### Reactions next to:

- Lung cancer
- Diffuse alveolar haemorrhage
- Airway obstruction

### Autoimmune diseases

- Polymyositis/dermatomyositis
- Rheumatoid arthritis
- Systemic sclerosis
- Systemic lupus erythematosus
- Sjögren syndrome
- Granulomatosis polyangiitis

### Inflammatory bowel diseases

### Injuries

- Aspiration
- Irradiation

### Transplantation

### Association with other interstitial lung diseases/patterns

- Nonspecific interstitial pneumonia
- Hypersensitivity pneumonitis
- Usual interstitial pneumonia
- Diffuse alveolar damage
- Chronic eosinophilic pneumonia

organising pneumonia have been ruled out, organising pneumonia is considered cryptogenic (*i.e.* COP).

Patients with COP typically present with a subacute illness of a relatively short duration (median  $< 3$  months) with variable degrees of cough and dyspnoea [2]. Systemic symptoms (fever and malaise) are common [3]. HRCT usually demonstrates patchy consolidation in a subpleural, peribronchial or bandlike pattern that often migrates and ground-glass opacities. Bronchial wall thickening, nodules, masses and reticular opacities are less commonly encountered. Small unilateral or bilateral pleural effusion may occur in 10–30% of patients [4, 5]. The reverse halo (or atoll) sign constitutes of central ground-glass opacity with surrounding air-space consolidation of crescentic and ring shape. Although seen in a minority of cases with COP, and

as demonstrated in our case, it may be helpful in suggesting the diagnosis [6, 7]. COP is regarded as the most common condition associated with reverse halo sign in immunocompetent patients [8, 9]. However, since several other diseases may present with reverse halo sign, this sign may not obviate the need for further diagnostic procedures (pathological confirmation). Such diseases include tuberculosis, fungal infections in immunocompromised hosts, sarcoidosis, granulomatosis with polyangiitis, pulmonary embolism and neoplastic disease [9, 10]. In pathology, the organising pneumonia pattern is a patchy process, primarily characterised by organising pneumonia involving alveolar ducts and alveoli with or without bronchiolar intraluminal polyps (bronchiolitis obliterans component) [1]. Our patient exhibited bronchiolar polyps. Some cases show more marked interstitial inflammation, such that there is overlap with cellular nonspecific interstitial pneumonia.

Diagnosis of COP is usually made by the combination of clinical, radiological, BAL and histological findings. BAL supports the diagnosis of COP mainly by excluding other diagnoses (malignancy, infection and haemorrhage) and by narrowing the differential diagnosis based on cellularity results [11]. BAL in COP is considered lymphocytic predominant of mixed cellularity, with foamy macrophages often observed, but these features are not typical for diagnosis. This is why the American Thoracic Society suggests performing BAL as an adjunct to the diagnostic evaluation of patients who lack a confident usual interstitial

pneumonia pattern on HRCT [11]. Histological confirmation of organising pneumonia may ideally warrant surgical lung biopsy since transbronchial lung biopsies often offer small and inadequate tissue samples unable to diagnose broader cohabitation to organising pneumonia pathology patterns (nonspecific interstitial pneumonia, hypersensitivity pneumonitis, usual interstitial pneumonia) or even adjacent malignancy. However, TBLB is an acceptable alternative in cases like ours, compatible with COP (acute illness, patchy infiltrates, BAL excluding other diagnoses) with a reported yield up to 69% [12]. In this era, transbronchial lung cryobiopsy (TBCB) was recently implicated and investigated in the management and diagnostic algorithm of interstitial lung diseases. Transbronchial lung cryobiopsy according to studies to date offers a diagnostic yield of 80%, mainly in diseases other than idiopathic pulmonary fibrosis interstitial lung diseases, more adequate tissue than TBLB and a lower procedure-related risk than surgical lung biopsy [13, 14]. The utility of this procedure in clinical practice remains to be established in the future.

The majority of patients with COP recover completely with oral corticosteroids at a starting dose of prednisone  $<0.5 \text{ mg}\cdot\text{kg}^{-1}$ , but relapse is common [2]. Reports have identified a subgroup of patients with organising pneumonia that does not completely resolve despite prolonged treatment. Some of these cases are characterised by residual or progressive interstitial fibrosis, with or without recurrent episodes of organising pneumonia [15].

## Affiliations

Andreas Afthinos<sup>1</sup>, Emmanouil Antonakis<sup>1</sup>, Maria Horti<sup>2</sup>, Eleftherios Markatis<sup>1</sup>, Konstantinos Pagratis<sup>1</sup>, Ilias C. Papanikolaou<sup>1</sup>

<sup>1</sup>Pulmonary Dept, Corfu General Hospital, Corfu, Greece. <sup>2</sup>Pathology Dept, Sismanoglio General Hospital, Athens, Greece. .

## Conflict of interest

A. Afthinos has nothing to disclose. E. Antonakis has nothing to disclose. M. Horti has nothing to disclose. E. Markatis has nothing to disclose. K. Pagratis has nothing to disclose. I.C. Papanikolaou has nothing to disclose.

## References

1. Travis WD, Costabel U, Hansell DM, *et al.* An Official American Thoracic Society/European Respiratory Society Statement: update of the international multidisciplinary classification of the idiopathic interstitial pneumonias. *Am J Respir Crit Care Med* 2013; 188: 733–748.
2. King TE Jr, Mortenson RL. Cryptogenic organizing pneumonitis: the North American experience. *Chest* 1992; 102: Suppl. 1, 8S–13S.
3. Drakopanagiotakis F, Paschalaki K, Abu-Hijleh M, *et al.* Cryptogenic and secondary organizing pneumonia: clinical presentation, radiographic findings, treatment response, and prognosis. *Chest* 2011; 139: 893–900.
4. Müller NL, Staples CA, Miller RR. Bronchiolitis obliterans organizing pneumonia: CT features in 14 patients. *AJR Am J Roentgenol* 1990; 154: 983–987.
5. Lee JW, Lee KS, Lee HY, *et al.* Cryptogenic organizing pneumonia: serial high-resolution CT findings in 22 patients. *AJR Am J Roentgenol* 2010; 195: 916–922.
6. Ujita M, Renzoni EA, Veeraraghavan S, *et al.* Organizing pneumonia: perilobular pattern at thin-section CT. *Radiology* 2004; 232: 757–761.
7. Kim SJ, Lee KS, Ryu YH, *et al.* Reversed halo sign on high-resolution CT of cryptogenic organizing pneumonia: diagnostic implications. *AJR Am J Roentgenol* 2003; 180: 1251–1254.
8. Godoy MC, Viswanathan C, Marchiori E, *et al.* The reversed halo sign: update and differential diagnosis. *Br J Radiol* 2012; 85: 1226–1235.
9. Walsh SL, Robertson BJ. Images in thorax. The atoll sign. *Thorax* 2010; 65: 1029–1030.

10. Zhan X, Zhang L, Wang Z, *et al.* Reversed halo sign: presents in different pulmonary diseases. *PLoS One* 2015; 10: e0128153.
11. Meyer KC, Raghu G, Baughman RP, *et al.* An official American Thoracic Society clinical practice guideline: the clinical utility of bronchoalveolar lavage cellular analysis in interstitial lung disease. *Am J Respir Crit Care Med* 2012; 185: 1004–1014.
12. Poletti V, Cazzato S, Minicuci N, *et al.* The diagnostic value of bronchoalveolar lavage and transbronchial lung biopsy in cryptogenic organizing pneumonia. *Eur Respir J* 1996; 9: 2513–2516.
13. Colby TV, Tomassetti S, Cavazza A, *et al.* Transbronchial cryobiopsy in diffuse lung disease: update for the pathologist. *Arch Pathol Lab Med* 2017; 141: 891–900.
14. Iftikhar IH, Alghothani L, Sardi A, *et al.* Transbronchial lung cryobiopsy and video-assisted thoracoscopic lung biopsy in the diagnosis of diffuse parenchymal lung disease: a meta-analysis of diagnostic test accuracy. *Ann Am Thorac Soc* 2017; 14: 1197–1211.
15. Lazor R, Vandevenne A, Pelletier A, *et al.* Cryptogenic organizing pneumonia: characteristics of relapses in a series of 48 patients. *Am J Respir Crit Care Med* 2000; 162: 571–577.